

## Skin diseases associated with *Malassezia* species

Aditya K. Gupta, MD, PhD, FRCPC,<sup>a,b</sup> Roma Batra, MPhil, PhD,<sup>b</sup> Robyn Bluhm, HBSc, MA,<sup>b,c</sup>  
Teun Boekhout, PhD,<sup>d</sup> and Thomas L. Dawson, Jr, PhD<sup>e</sup>  
*Toronto and London, Ontario, Canada; Utrecht, the Netherlands; and Cincinnati, Ohio*

The yeasts of the genus *Malassezia* have been associated with a number of diseases affecting the human skin, such as pityriasis versicolor, *Malassezia (Pityrosporum)* folliculitis, seborrheic dermatitis and dandruff, atopic dermatitis, psoriasis, and—less commonly—with other dermatologic disorders such as confluent and reticulated papillomatosis, onychomycosis, and transient acantholytic dermatosis. Although *Malassezia* yeasts are a part of the normal microflora, under certain conditions they can cause superficial skin infection. The study of the clinical role of *Malassezia* species has been surrounded by controversy because of their fastidious nature in vitro, and relative difficulty in isolation, cultivation, and identification. Many studies have been published in the past few years after the taxonomic revision carried out in 1996 in which 7 species were recognized. Two new species have been recently described, one of which has been isolated from patients with atopic dermatitis. This review focuses on the clinical, mycologic, and immunologic aspects of the various skin diseases associated with *Malassezia*. It also highlights the importance of individual *Malassezia* species in the different dermatologic disorders related to these yeasts. (J Am Acad Dermatol 2004;51:785-98.)

Although yeasts of the genus *Malassezia* are a normal part of the skin flora, they are also associated with several common dermatologic conditions. It has been generally accepted that pityriasis versicolor and *Malassezia (Pityrosporum)* folliculitis are caused by *Malassezia* yeasts. In the case of seborrheic dermatitis (SD) and dandruff (SD/D), the causal role of *Malassezia* has become clear, but the role of specific species is still being defined. In atopic dermatitis (AD) and psoriasis, the evidence for a causal relationship remains less defined. However, there have been reports in the literature linking all these disorders with the *Malassezia* yeasts. In general, because of their dependence on lipids for survival, *Malassezia* yeasts are most often found in sebum-rich areas of the skin such as the trunk, back, face, and scalp. Less frequently, they may also be found on other areas of the body including arms, legs, and genitalia. In some cases, these areas may

also be affected by the clinical conditions associated with *Malassezia*. However, in the vast majority of patients, skin involvement is localized to specific areas of the skin. In the past, it was believed that this genus (then known as *Pityrosporum*) consisted of two species, which could often be differentiated on the basis of cellular morphology. In addition, reports using the older *Pityrosporum* taxonomy suggested that the relative prevalence of *P orbiculare* and *P ovale* varied with both body site<sup>1</sup> and geographic location of patients.<sup>2</sup>

All *Malassezia* species have distinct morphologic characteristics that allow them to be differentiated from other yeasts. However, the use of molecular markers is essential to assign the correct taxonomic position to the individual species. In 1996, Guého et al<sup>3</sup> revised the *Malassezia* genus using morphology, ultrastructure, physiology, and molecular biology, and classified the genus into 7 species: *M globosa*; *M restricta*; *M obtusa*; *M slooffiae*; *M sympodialis*; *M furfur*; and the nonlipid dependent *M pachydermatis*. The recent identification of two new *Malassezia* species, *M dermatis*<sup>4</sup> and *M equi*<sup>5</sup> (not yet formally described, but tentatively named), has further substantiated the need for molecular techniques to distinguish the various *Malassezia* species. With the revision of the taxonomy of *Malassezia*, there has been a renewal of interest in their clinical importance. The development of physiologic and molecular techniques for distinguishing between the 7 recognized species has led to new research that examines the relationship between

From the Division of Dermatology, Department of Medicine, Sunnybrook and Women's College Health Science Center (Sunnybrook site) and the University of Toronto<sup>a</sup>; Mediprobe Research Inc, London<sup>b</sup>; University of Western Ontario, London<sup>c</sup>; Centraalbureau voor Schimmelcultures, Utrecht<sup>d</sup>; and Proctor and Gamble, Cincinnati.<sup>e</sup>

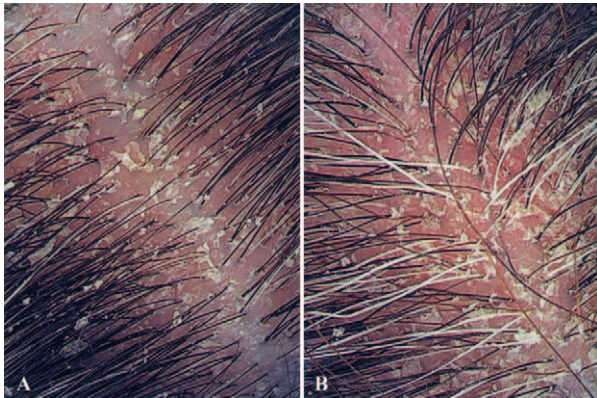
Supported in part by a grant from Proctor and Gamble.

Disclosure: Supported in part by a grant from Proctor and Gamble. Reprint requests: Aditya K. Gupta, MD, PhD, FRCPC, 645 Windermere Rd, London, Ontario, Canada N5X 2P1. E-mail: agupta@execulink.com.

0190-9622/\$30.00

© 2004 by the American Academy of Dermatology, Inc.

doi:10.1016/j.jaad.2003.12.034



**Fig 1.** Dandruff (A) and seborrheic dermatitis (SD) (B) on scalp. Note larger, yellowish scale and scalp erythema in SD versus dandruff.

these yeasts and skin disease. Several culture-based and molecular techniques have been evaluated for their use to distinguish the *Malassezia* species. Gupta et al<sup>6</sup> and Nakabayashi et al<sup>7</sup> successfully conducted culture-based assays on samples from patients with pityriasis versicolor, SD, and AD, and from control subjects.<sup>6-8</sup> However, culture-based methods can be biased because of different growth rates and culture requirements of different species. Therefore, the emphasis is now on molecular techniques. Recently, Gemmer et al<sup>9</sup> devised a specific and highly sensitive molecular method, terminal fragment length polymorphism, suitable for the rapid and reliable identification of *Malassezia* species from very small clinical samples. Polymerase chain reaction restriction endonuclease analysis, amplified fragment length polymorphism analysis, and pulsed field gel electrophoresis are the other molecular techniques that have been successfully used by Gupta et al,<sup>10</sup> Theelen et al,<sup>11</sup> and Boekhout et al,<sup>12</sup> respectively.

The sole nonobligatory lipophilic species, *M pachydermatis*, is primarily zoophilic, although it has occasionally been isolated from human skin and has also been implicated in nosocomial systemic *Malassezia* infections.<sup>13-15</sup> *M furfur* has also been implicated in several nosocomial outbreaks.<sup>16-18</sup> *M globosa* matches the original description of *Pityrosporum orbiculare*, whereas *M restricta* visually resembles *Pityrosporum ovale*.<sup>9</sup> Of the 6 lipophilic species—*M obtusa*, *M restricta*, *M slooffiae*, *M sympodialis*, *M furfur*, and *M globosa*—there is some question as to which species are more commonly found on human skin, whether there is variation in the distribution of the yeasts on different body sites, and whether there is geographic variation in species prevalence. Two new species have recently been described: *M dermatis* isolated from

patients with AD; and *M equi* (tentatively named) isolated from skin of healthy horses.<sup>4,5</sup> There is also the clinical question of whether there is a relationship between particular *Malassezia* species and various dermatologic disorders, as different authors have debated whether *Malassezia* yeasts are of primary pathogenic significance or a secondary phenomenon. This review will discuss the skin diseases associated with *Malassezia* yeasts and discuss the evidence for individual species being associated with a given condition.

### SD/D

SD/D is perhaps the most common disease associated with *Malassezia* yeasts, occurring in 1% to 3% of the general population.<sup>19,20</sup> The incidence of SD/D is much higher in patients who are immunocompromised, especially those with AIDS, ranging from 30% to 33%.<sup>21,22</sup> Dandruff has recently received much attention, as its presence can lead to loss of self-esteem and a negative social image.<sup>20</sup> It is a disorder that is generally discussed alongside SD because of the scaling effect of the scalp. The relationship between SD and dandruff has been controversial. Some investigators regard a diagnosis of SD of the scalp as a way of describing severe dandruff, whereas others believe that the term “dandruff” should be used for any flaking of the scalp, regardless of origin.<sup>23-26</sup> The resurgence of interest in the role of *Malassezia* yeasts in the development of SD/D has provided additional evidence that, in most cases, dandruff is a mild form of SD. Some authors believe that dandruff is a noninflammatory form of SD.<sup>20,27,28</sup> Considering all available data, we consider SD and dandruff to be differing severity manifestations of similar origin, and we will, therefore, discuss them together in this review (Fig 1).<sup>20,29</sup>

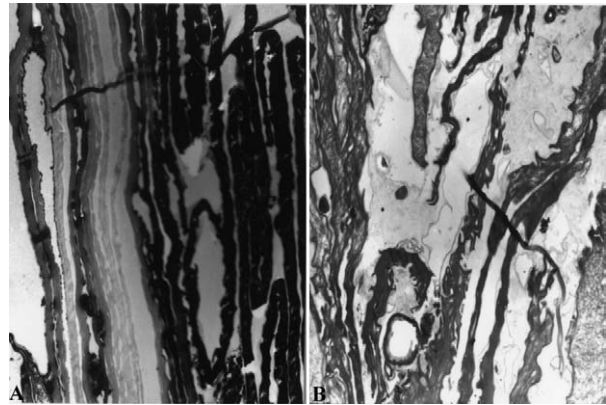
The vast majority of more recent data supports a direct causal link between *Malassezia* and dandruff. First, effective treatment of the condition can occur with a wide range of material types, from zinc salts and selenium salts to highly specific azoles, and the only known functional link between these materials is their antifungal activity.<sup>30</sup> The second supporting factor is that improvement in SD/D is accompanied by a reduction in *Malassezia* levels on the scalp.<sup>31</sup> Although the absolute level of *Malassezia* does not appear to correlate with the condition, its reduction, among those individuals who express the symptoms, strongly supports its role. The nature of why some individuals are susceptible and others are not is less clearly defined and will require further research into individual susceptibility.

Other diseases associated with SD/D are Parkinson's disease, depression, spinal injuries,<sup>32</sup> and pityriasis versicolor. They are somewhat more common in male patients than in female patients, and tend to occur most frequently in adolescents and young adults, and again in adults older than 50 years.<sup>24</sup> The association of SD/D with adolescents and young adults is most likely caused by the increase in sebaceous activity during puberty.<sup>33,34</sup> The disease appears to be influenced by seasons. The lesions worsen during winter, whereas sunlight seems to improve the clinical appearance of the disease. It is interesting to note, however, that *Malassezia* secretes a potent UV protectant (Pityriacitrin) that confers resistance to UV radiation.<sup>35,36</sup>

The lesions of SD vary in appearance. The characteristic presentation is patches of red, flaking, greasy skin, particularly on the scalp, nasolabial folds, ears, eyebrows, and chest. However, patients often vary with the degree of erythema, amount of flaking, and the extent to which the affected areas have a greasy appearance. It is also important to note that, although patients with SD may have oily skin, this is not necessarily the cause.<sup>37</sup> Although less severe than SD, dandruff is characterized by patches of loosely adherent, oily flakes, often accompanied by pruritus. Also, dandruff does not exhibit the overt inflammation seen in SD, and is confined to the scalp.

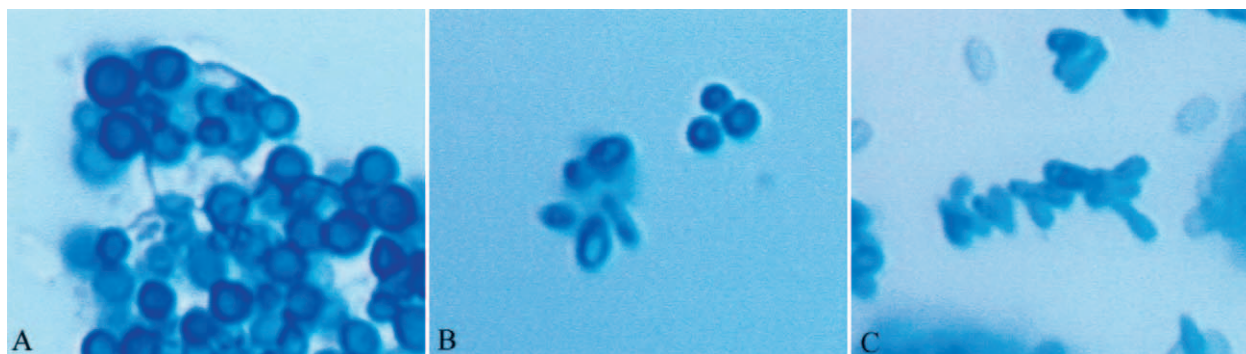
Early investigators suggested that the *Malassezia* yeasts might play a role in the cause of SD/D<sup>38,39</sup>; however, researchers later began to view this condition as the result of hyperproliferation. This hypothesis was in part because of the effectiveness of keratolytic and anti-inflammatory agents (eg, salicylic acid and corticosteroids) in the treatment of SD. Keratolytic therapy is much less effective in dandruff than SD, perhaps because of the lower severity of the inflammation and hyperproliferation. Topical treatment has previously been effective with broad-spectrum antimicrobials such as selenium sulfide and zinc pyrithione. However, their nonspecificity toward bacteria and fungi, coupled with their keratolytic and anti-inflammatory effects, respectively, have complicated the definition of the specific causal organism or organisms. With the development of effective and highly specific antifungal agents such as the azoles, hydroxypyridones, and allylamines, the focus began to switch to the study of fungal skin flora, particularly the *Malassezia* yeasts.

The proportion of *Malassezia* yeasts on the scalp is higher for patients with SD/D than in control subjects (Fig 2).<sup>40</sup> There are conflicting data regarding the number of yeasts in lesional versus non-lesional skin. Some have reported a decrease in the



**Fig 2.** Normal (A) and dandruff (B) scalp stratum corneum. Note closely apposed corneocytes and normal intercellular lipid structures (A) and increased intercellular lipid, prevalence of intracellular lipid droplets, corneocyte interdigitation, and *Malassezia* cell (identifiable by scalloped cell wall) in lower left (B). (A and B, Electron micrograph; original magnifications: A,  $\times 8100$ ; B,  $\times 7500$ .)

density of *Malassezia* recovered from lesional skin,<sup>6</sup> whereas others have shown a greater number of yeasts in lesional skin,<sup>4</sup> a greater detectable incidence in affected patients,<sup>9,24</sup> or no difference.<sup>18</sup> It has been suggested that SD is not caused by an overgrowth of the *Malassezia* yeasts, but by an abnormal host response to the yeasts on the skin.<sup>41</sup> However, patients with SD do not appear to have higher total antibody levels than control subjects.<sup>42</sup> Moreover, there is conflicting evidence regarding IgG antibodies in particular; some investigators have found an increase in IgG levels in patients,<sup>43</sup> whereas others have shown that the elevated IgG antibody titers are not related to *Malassezia*.<sup>41</sup> Midgley<sup>44</sup> demonstrated that 72.5% patients with SD had precipitating antibodies against *M globosa*, in contrast with control subjects. It has been suggested that the lesions of SD are caused by toxin production or by the lipase activity of *Malassezia*.<sup>42</sup> The enzyme lipase splits triglycerides into irritant fatty acids that may induce scaling<sup>25,45</sup> or releases arachidonic acid, which is involved in the inflammation of skin.<sup>46-48</sup> It has also been suggested that impaired cell-mediated immunity may facilitate fungal survival in the skin.<sup>49</sup> Further, Faergemann<sup>50</sup> detected increased numbers of NK1<sup>+</sup> and CD16<sup>+</sup> cells, in combination with complement activation, during their investigation of immune response of a sample of patients with SD. In addition, elevated numbers of activated (HLA-DR4-positive) lymphocytes have been detected in the circulation of certain patients with SD, prompting the hypothesis that intermittent activation of the immune system may have occurred.<sup>51</sup> Moreover, Watanabe et al<sup>52</sup> demonstrated that *Malassezia* yeast



**Fig 3.** *Malassezia* species cultured in modified Dixon broth. **A**, *M globosa*; **B**, *M restricta*; **C**, *M furfur*. (Original magnification:  $\times 600$ .)

species can differentially induce human cytokine production by means of keratinocytes. Taken as a whole, the above-cited studies strongly support the contention that *Malassezia* yeasts contribute to the pathogenesis of SD.

As with pityriasis versicolor, the revision of the *Malassezia* taxonomy sparked new research into the relationship between the 8 lipophilic species and the clinical entities associated with the yeasts. The species that have been shown to be most closely associated with SD/D to date are *M globosa*<sup>6,7,24,53</sup> and *M restricta*.<sup>9,24,53</sup> However, some authors have also reported *M furfur*, *M sympodialis*, *M obtusa*, and *M slooffiae*.<sup>7</sup> Interestingly, whereas Nakabayashi et al<sup>7</sup> found that *M globosa* was isolated with the same frequency from both lesional and nonlesional skin, Gupta et al<sup>6</sup> found that significantly more *Malassezia* yeasts could be cultured from nonlesional skin. Given that previous studies have failed to find this difference, the results of this study may represent an artifact of the sampling procedure; Gupta et al<sup>6</sup> used contact plates filled with Leeming-Notman agar, whereas Nakabayashi et al<sup>7</sup> used the swab and tape method. Similarly, Sandström et al,<sup>54</sup> using contact plates, cultured significantly fewer *Malassezia* yeasts from lesional than from nonlesional skin. However, in this study, this was only the case with one *Malassezia* species, *M globosa*. Two other species, *M sympodialis* and *M obtusa*, were often cultured from both lesional and nonlesional skin of patients with SD. Gemmer et al,<sup>9</sup> using DNA-based detection, report a significantly higher detection rate for both *M globosa* and *M restricta* in patients with SD/D. They suggest that the difficulty in culturing *M restricta* and *M globosa* has resulted in their presence being underreported by culture-based methods, relative to the culturally robust *M furfur*, *M sympodialis*, and *M slooffiae* (Fig 3). Gupta et al<sup>6</sup> have suggested that the use of synthetic detergents and shampoos by patients may represent factors that lead to reduced

colony counts and, hence, differences in results in the various studies.

There is also a possibility that SD of the scalp and of the trunk may prove to be associated with different species, as there is already evidence that different *Malassezia* species tend to be found on different body sites<sup>6,55</sup> in both normal and diseased skin. Development of new, more species-specific molecular diagnostics<sup>9,10,56,57</sup> is currently clarifying the picture, but further work will be necessary by applying these techniques to more patients.

### PITYRIASIS VERSICOLOR

Pityriasis versicolor is a chronic superficial fungal disease that is characterized by the appearance of round to oval lesions, most commonly found on the trunk and upper aspects of the arms. These lesions vary in color, and can be hypopigmented (white) or hyperpigmented (pink, tan, brown, or black). Flaking is evident, although in larger lesions this may occur only at the border. Lesions may be round or oval, becoming confluent in advanced cases of the disorder. Generally, pityriasis versicolor is regarded as a cosmetic disorder, as most patients are asymptomatic. However, pruritus does occur in some cases. The disease often has a relapsing nature and needs to be treated frequently.<sup>50</sup>

Although some cases of pityriasis versicolor have been reported in children<sup>58,59</sup> and infants,<sup>60,61</sup> the disease is most commonly found in adolescents and young adults when the sebaceous gland activity is maximal. It is postulated that this disease occurs when the *Malassezia* yeasts that normally colonize the skin change from the round, yeast form to a pathologic mycelial form, which then invades the stratum corneum of the skin. Although pityriasis versicolor tends to be more prevalent in the summer months and in tropical locations than in temperate regions, evidence points to the importance of endogenous host factors in the development of the

disease. These may include malnutrition,<sup>62</sup> use of oral contraceptives,<sup>63</sup> use of systemic corticosteroids or immunosuppressants, and hyperhidrosis.<sup>64,65</sup>

Pityriasis versicolor is diagnosed on the basis of its clinical appearance and the diagnosis can be confirmed by microscopy. Clinically, pityriasis versicolor can resemble other dermatologic disorders, and differential diagnosis should include vitiligo (particularly in patients with dark skin and hypopigmented lesions), tinea corporis (in this instance, the causative organism is a dermatophyte rather than a yeast as in pityriasis versicolor), SD, pityriasis rosea, pityriasis alba, chloasma, erythrasma, confluent and reticulated papillomatosis of Gougerot and Carteaud, pityriasis rotunda,<sup>66-68</sup> secondary syphilis, and pinta. Although pityriasis versicolor is most commonly seen on the trunk and arms, it may also occur on the face,<sup>69</sup> scalp,<sup>70,71</sup> and other areas of the body,<sup>72,73</sup> either in addition to the more common distribution of lesions or as the sole area of involvement.

The diagnosis of pityriasis versicolor can also be made using microscopy or Wood's light examination (filtered UV light with a peak of 365 nm). A specimen for microscopy should be taken from the scaling edge of a lesion, as these areas are most likely to contain viable organisms.<sup>62</sup> The keratin and debris in the specimen should be dissolved using either 10% to 15% potassium hydroxide or Albert's solution.<sup>74</sup> Staining of the residual fungal elements will reveal a characteristic spaghetti-and-meatballs appearance, reflecting the presence of both hyphae and spores. It has been reported by some authors that the number of yeast and hyphae in the lesions of pityriasis versicolor is greater than in normal skin,<sup>75</sup> whereas others have shown that the difference is not statistically significant.<sup>6,7</sup>

In addition to microscopic examination, Wood's light examination may be used where pityriasis versicolor lesions may fluoresce a characteristic bright yellow or gold color. The color of the fluorescence may also aid in differential diagnosis, as it is unique to the mycelial form of *Malassezia*. However, a positive Wood's light examination response is seen in only one third of the cases,<sup>76</sup> limiting the usefulness of this test. Recent evidence<sup>77,78</sup> suggests that only *M furfur* produces the indole compounds that fluoresce under Wood's light, indicating that this species is implicated in at least some cases of pityriasis versicolor.

In general, it seems that the most common *Malassezia* species cultured from lesions of pityriasis versicolor are *M globosa*<sup>7,79</sup> and *M sympodialis*.<sup>6,8</sup> Other species such as *M slooffiae* and *M furfur* are relatively less common but not completely absent. The differences between the studies may be a result

of geographic variation in species prevalence, although further investigation is required to confirm this hypothesis. However, there is evidence that these species are also common on both nonlesional skin of patients with pityriasis versicolor and on skin of control subjects, suggesting that the endogenous factors that promote the development of pityriasis versicolor in susceptible hosts do not necessarily favor the growth of some species over others.

### ***MALASSEZIA (PITYROSPORUM)* FOLLICULITIS**

Like pityriasis versicolor, *Malassezia* folliculitis is associated with a clear pattern of *Malassezia* colonization. Although the transformation of the yeast cells to their hyphal form is unique to pityriasis versicolor, histologic examination of patients with *Malassezia* folliculitis shows, as the name suggests, invasion of the hair follicles with large numbers of *Malassezia* yeasts.<sup>80</sup> This invasion results in the development of erythematous papules, and sometimes pustules, which may be either asymptomatic or pruritic. *M furfur* (orbiculare or ovale) is detected in follicular contents of steroid acne and acne vulgaris.<sup>81</sup> Usually *Malassezia* yeasts are present along with staphylococci and propionibacteria in the follicles.<sup>82</sup> Some authors<sup>83</sup> claim that *Malassezia* folliculitis is actually a polymorphic disorder. They describe the most common lesion as a molluscoid, dome-shaped comedopapule (2-3 mm in diameter) with a central "dell" representing the follicle. However, they also report that in severe cases, patients may also have pustules, nodules, and cysts. It is important to note that these authors were working in a tropical climate (the Philippines), and that this may provoke more severe cases of *Malassezia* folliculitis than tend to occur in more temperate regions. In most cases of folliculitis, if the biopsy specimen is cut in serial sections, a typical dilated follicle will contain abundant round budding yeast cells and sometimes hyphae will also be found.<sup>84</sup> Also, the organism is seen on direct microscopic examination, usually in the absence of other micro-organisms.<sup>84</sup> These arguments strongly support the pathogenic role of *Malassezia* in this disease. Pityriasis versicolor has been shown to be more common in tropical countries<sup>85</sup> and it is possible that the climate may also affect the severity of *Malassezia*-related diseases. Like pityriasis versicolor, *Malassezia* folliculitis occurs mainly on the back, chest, and upper aspects of the arms.<sup>80,86</sup> In some geographic regions, particularly humid and tropical areas, the face is also commonly involved.

At a histologic level, *Malassezia* folliculitis is marked by the presence of an inflammatory infiltrate consisting of lymphocytes, histiocytes, and

neutrophils, along with focal rupture of the follicular epithelium.<sup>86-88</sup> Spheric and budding yeast cells have been demonstrated in histopathology by methanamine silver— and periodic acid-Schiff—stained sections from biopsy specimens.<sup>84,87</sup> Also, circulating IgG antibodies against *P ovale* are present in high titres.<sup>49</sup> The inflammatory response may be a result, in part, of the ability of the *Malassezia* yeasts to hydrolyze triglycerides into free fatty acids.<sup>84,88-90</sup> The hair follicles themselves also have a characteristic appearance; they tend to be dilated and distended and are often full of keratinous material.<sup>83</sup> It has also been suggested that the overgrowth of the yeasts is a secondary occurrence, permitted by the occlusion of the follicle.<sup>91</sup>

As with the other skin conditions associated with the *Malassezia* yeasts, the development of *Malassezia* folliculitis appears to have an immune component. It has been reported to occur in individuals who are immunosuppressed.<sup>90,92-94</sup> Moreover, the eosinophilic folliculitis seen in patients with HIV and AIDS may also be marked by colonization of the follicles with *Malassezia* yeasts.<sup>95,96</sup> Other predisposing factors are diabetes mellitus, immunosuppression as a result of heart transplant, and the use of broad-spectrum antibiotics.<sup>49,93</sup>

We could not find any literature examining the possibility that one or more species of *Malassezia* may be more commonly involved in *Malassezia* folliculitis. This may be because the available studies have taken samples from the skin surface using techniques that might not reach the yeasts located in the deeper aspects of the hair follicle.

## AD

AD is a chronic inflammatory disorder marked by pruritus (often intense) and characteristic eczematous lesions with erythema, fine scaling, and thickening of the epidermis. Genetic factors are known to play an important role in the development of this disorder and many patients have a family history of AD, allergic rhinitis, asthma, or a combination of these. If both parents are carriers of the disease, the risk for children is as high as 70%.<sup>97</sup> In many patients, AD is present from childhood and between 60% and 70% of patients with this childhood syndrome outgrow the disorder.<sup>98,99</sup> In adults, the incidence of AD has been estimated to be 2%.<sup>98,99</sup> Adult-onset AD is relatively uncommon. The incidence of AD is on the rise in Western countries.<sup>100</sup>

*Malassezia* yeasts appear to be a particularly important factor in the cause of AD in adults, especially those in whom the disease is localized to the head and neck.<sup>101-113</sup> *Malassezia* yeasts have

been cultured from 83% of adult patients with this form of AD,<sup>101</sup> and it has also been shown that these patients respond to systemic ketoconazole.<sup>114</sup> Because the yeasts are also frequently colonized from control subjects, it has been hypothesized that they act as allergens in patients who are susceptible, rather than as infectious agents.<sup>107,115</sup> This hypothesis has been supported by the demonstration that patients with AD have positive patch test reactions to the yeasts.<sup>116</sup> Recently, molecular work has also elucidated the structure of some allergens derived from *Malassezia* yeasts.<sup>117,118</sup> There are several reports that have documented that patients with AD have higher levels of IgE antibodies.<sup>84,111,119-121</sup> In these studies, specific *Malassezia* IgE antibodies were found in 20% to 100% of the patients with AD. Approximately 40% to 65% of patients with AD have IgE antibodies and/or skin reactivity against *M furfur*, and a higher T-cell response against this yeast is found in patients with AD than in healthy individuals.<sup>122</sup> Zargari et al<sup>123</sup> evaluated the presence of IgE antibodies to different *Malassezia* species in patients with AD, and concluded that the use of only one species of *Malassezia* species is not sufficient to detect all patients IgE-sensitized to *Malassezia*, and that various *Malassezia* species contained species-specific antigens. Koyama et al<sup>124</sup> reported similar results. Several IgE binding components of *Malassezia* species have been isolated.<sup>117,125-130</sup> There are 3 major allergen components that have been identified in *Malassezia* yeasts, two protein components of 67-kd and 37-kd each, and one carbohydrate component of 14-kd.<sup>130</sup> Rasool et al<sup>122</sup> cloned 5 different IgE-binding proteins (Mal f5, Mal f6, MF7, MF8, and MF9) from *M furfur* and found that all of the recombinant proteins had the ability to bind serum IgE from patients with AD. Another study indicates that a glycoprotein, Malg46b of *M globosa*, is dominantly expressed in this fungus and is a possible major antigen for IgE antibodies in patients with AD.<sup>131</sup> Recent work has also indicated that AD is linked to a family of cytokine genes (IL-3, IL-4, IL-5, IL-13, and granulocyte-macrophage colony stimulating factor) located on chromosome 5q31-33.<sup>132,133</sup>

Because yeasts appear to be involved in only a subset of patients with AD, there has been little research into their role in this disease, compared with work done on the conditions described above. However, some studies have examined the prevalence and the species composition of *Malassezia* yeasts for patients with AD. Sandström et al<sup>54</sup> sampled skin on the upper aspect of the back, and found that *M sympodialis* was the species most commonly isolated from both patients with AD and control

subjects. These investigators were able to sample both lesional and nonlesional skin and found a significant difference, with the yeasts being more common in nonlesional skin. Gupta et al<sup>6</sup> found that the mean number of colony-forming units grown from samples taken from patients with AD was significantly lower than that obtained from sampling control subjects. In both groups, however, the dominant species was *M sympodialis*, cultured in 51% of the patients. Johansson et al<sup>108</sup> found that cultures were positive in 56% of patients with AD (70 of 125), and *M sympodialis* was cultured in 40% of the patients with positive culture. Sugita et al<sup>57</sup> reported that *M restricta*, *M globosa*, and *M furfur* are present in significantly higher frequencies in patients with AD than in control subjects.

Nakabayashi et al<sup>7</sup> found that *M furfur* was isolated more frequently from lesional skin (21%) than from nonlesional skin (11%) of patients with AD. However, this difference was not significant and the authors' caution that the data are not sufficient to prove that *M furfur* exacerbates AD. In addition, these authors found that *M globosa* was cultured from 33% of samples from nonlesional skin and only 14% of samples from lesional skin. Gupta et al<sup>6</sup> sampled lesional skin and found that *M sympodialis* was the species most commonly isolated from both patients with AD and control subjects. Sandström et al<sup>54</sup> found a difference in species distribution on lesional versus nonlesional skin in patients with AD; nonlesional skin was most frequently colonized by *M globosa*, whereas *M sympodialis* was most commonly found on lesional skin.

Sugita et al<sup>4</sup> recently reported a new *Malassezia* species, *M dermatis*, from the skin of patients with AD. During examination of the cutaneous colonization of *Malassezia* species for patients with AD, they found this new species on the surface of the patients' skin. A total of 19 patients with AD were included in this study. A total of 5 strains of *M dermatis* could be isolated from two patients. Three strains were isolated from a single patient, whereas the other two were found on one patient each. The physiologic characteristics of *M dermatis* are identical to those of *M furfur*, but taxonomically it is placed close to *M sympodialis*. The sequence analysis of recombinant DNA from the 26S and ITS regions convinced these authors that the 5 strains represent a distinct species, rather than a variant of *M sympodialis*.

Not only *Malassezia*, but also bacteria, especially *Staphylococcus aureus*, and other yeasts and filamentous fungi, such as *Candida* species and *Trichophyton rubrum*, have been correlated with AD.<sup>134-138</sup> However, *S aureus* infection is more likely to be a secondary cause of AD whereas *Malassezia*

yeasts are recognized as being the primary causative agent for AD.<sup>139</sup>

## PSORIASIS

The role of *Malassezia* species in psoriasis is still undetermined, but several reports have associated these lipophilic yeasts with the development of skin lesions in psoriasis. Psoriasis is characterized by hyperproliferation and hyperkeratinization of the epidermis. The cases most commonly associated with the yeasts are those that tend to involve the scalp.<sup>140</sup> Again, this hypothesis is supported by the response of scalp psoriasis to ketoconazole,<sup>141</sup> and also by analysis of the association between scalp psoriasis and the presence of *M ovalis* (possibly corresponding to the species *M restricta*) yeasts on the scalp.<sup>142</sup> However, it has recently been suggested that the *Malassezia* yeasts may also play a role in psoriasis of the glans penis.<sup>143</sup>

Clinically, the lesions of psoriasis may resemble those of SD; however, the histologic appearance of the lesions is distinct. Biopsy specimens taken from patients with SD show a spongiform appearance,<sup>144</sup> although older lesions may lose this characteristic and begin to resemble psoriasis. These lesions are often characterized by the presence of follicular plugs of orthokeratotic and parakeratotic cells, and uneven rete ridges.

Psoriasis is also known to have a strong genetic component. Therefore, research has investigated immune reactions for patients with psoriasis. It has been shown that these individuals have immunologic responses to both *Malassezia* yeasts and to proteins derived from them. T cells reactive to the yeasts have been isolated from lesional skin<sup>145</sup> and it has been demonstrated that antibodies to the yeasts are present in serum taken from patients with psoriasis, but not from control subjects.<sup>146</sup> Kanda et al<sup>147</sup> found that *Malassezia* yeasts induce Th-1—and Th-2—related cytokine, chemokine, and prostaglandin E2 production in peripheral blood mononuclear cells from patients with psoriasis vulgaris.

Gupta et al<sup>6</sup> have found that, of the 6 *Malassezia* species they recovered from all patients, *M globosa* was most frequently isolated from patients with psoriasis and those with SD. This species was also isolated from the scalp, forehead, and trunk with equal frequency. However, a recent study has reported significant differences in the distribution of *Malassezia* species between psoriatic and healthy scalp skin, and in the distribution of *Malassezia* species according to the severity of the scalp involvement.<sup>148</sup> They reported that *M globosa* in its yeast phase was the predominant species (55%) in patients with psoriasis, followed by *M slooffiae*

(18%), and *M restricta* (10%), the latter being the most common species isolated from healthy scalp skin.

### OTHER DERMATOLGIC DISORDERS

There have been a few scattered case reports in the literature associating *Malassezia* yeasts with various other skin conditions. In particular, *Malassezia* has been shown to be involved in at least some cases of confluent and reticulated papillomatosis.<sup>149-151</sup> In one case, the patient was successfully treated using selenium sulfide, a traditional topical treatment for pityriasis versicolor. A possible link between *Malassezia* and transient acantholytic dermatosis has also been suggested,<sup>152</sup> again on the basis of the response of the disorder to selenium sulfide. Finally, although up to 90% of cases of onychomycosis are caused by dermatophytes, there have been several reports in the literature<sup>153,154</sup> of patients with onychomycosis from whom *Malassezia* yeasts have been isolated. Yeasts do not normally colonize nails, as they are not a good source of lipids. It is possible, however, that their presence in these cases represented a secondary infection in patients with onychomycosis.

### TREATMENT

Most of the literature addressing the treatment of the conditions discussed in this article is concerned with those diseases most closely linked to *Malassezia* yeasts: pityriasis versicolor; SD/D; and *Malassezia* folliculitis. In the case of the other conditions, there are isolated reports of the efficacy of selenium sulfide (for confluent and reticulated papillomatosis and for transient acantholytic dermatosis) or ketoconazole (for AD and scalp psoriasis), as described above.

*Malassezia* yeasts are susceptible to a wide range of nonspecific and specific antifungal topical treatments, and several effective oral agents. Older treatments tend to lack antifungal activity and generally possess keratolytic properties. These agents include selenium sulfide, propylene glycol, and sulfur- and tar-containing compounds. However, the activity of selenium sulfide and propylene glycol can be accounted for by their antimicrobial activity.<sup>155-157</sup> Zinc pyrithione is particularly effective in SD/D, because of both potent antimicrobial (effective against bacteria and fungi) and anti-inflammatory activities, killing *Malassezia* and causing a decrease in IL-1 release from cultured keratinocytes.<sup>158</sup> Specific antifungal agents used for the topical treatment of *Malassezia* infections, particularly pityriasis versicolor and SD, include the azoles (ketoconazole, bifonazole, clotrimazole, itraconazole, fluconazole, miconazole, econazole, fenticonazole, metronida-

zole, sulconazole, tioconazole, imidazole),<sup>159,160,161</sup> hydroxypyridones (ciclopirox olamine),<sup>162</sup> allylamines (terbinafine),<sup>163</sup> benzylamines (butenafine),<sup>164</sup> tacrolimus,<sup>165,166</sup> and pimecrolimus.<sup>165</sup>

Several oral agents have also been used successfully to treat *Malassezia* infections. Faergemann<sup>97</sup> has suggested that oral treatment may be more effective than topical in *Malassezia* (*Pityrosporum*) folliculitis because it more effectively eradicates the *Malassezia* yeasts located deep inside in the follicle. Ketoconazole was the first effective oral azole and has been used to treat pityriasis versicolor,<sup>167,168</sup> SD,<sup>169</sup> and *Malassezia* folliculitis.<sup>170</sup> It has also been shown to be effective in head and neck AD<sup>102</sup> and in scalp psoriasis.<sup>141</sup> More recently, itraconazole<sup>171,172</sup> and fluconazole<sup>173,174</sup> have been reported to be effective treatments of pityriasis versicolor and SD. Itraconazole is recommended when resistance to topical preparation is observed.<sup>171</sup> Oral administration of itraconazole also appears to delay relapses in *Malassezia* folliculitis.<sup>171</sup> According to Caputo and Barbareshchi,<sup>171</sup> itraconazole may be regarded as a first choice in *Malassezia*-linked dermatoses (like *Malassezia* folliculitis), in difficult to treat clinical forms of SD, and an alternative for AD, rosacea, perioral dermatitis, and palmoplantar pustulosis.

Although oral terbinafine is not effective for pityriasis versicolor, it has recently been reported to be effective in SD.<sup>175</sup> The reason as to why the topical route of administration of terbinafine is more effective in treating pityriasis versicolor, compared with the oral route, is not completely understood. One possible reason might be that although topical treatment may be sufficient to kill all superficially located *Malassezia* yeasts, such a treatment might result in an uneven distribution of the drug in the dermis, epidermis, sebum, stratum corneum, and deeper layers of skin such as pilosebaceous follicles.<sup>176</sup> On the other hand, with oral therapy, the drug would be more evenly distributed in the pilosebaceous follicles and skin surface lipids, but if the concentrations were marginal, they would only be effective against the most susceptible *Malassezia* strains.<sup>176</sup> Gupta et al<sup>177</sup> have already shown that the *Malassezia* species vary in their in vitro susceptibility to various antifungal agents, including terbinafine. Moreover, orally administered terbinafine may not be circulated effectively to body regions with a greater number of sebaceous glands. Because these sites often have higher *Malassezia* counts, the effectiveness of the drug may be reduced.

Traditionally, SD has been treated with either topical or oral steroids.<sup>178</sup> However, the renewed interest in the role of *Malassezia* yeasts in this condition has made antifungal medications an



increasingly popular choice. Tacrolimus has been shown to have potent antifungal activity against *M furfur* in vitro.<sup>166</sup> It has been suggested that topical tacrolimus and pimecrolimus may be superior alternatives to corticosteroids, as they exhibit anti-inflammatory activity but do not have the side effects associated with long-term corticosteroid use.<sup>165</sup>

Both pityriasis versicolor and SD/D tend to recur in patients who are vulnerable, often with a seasonal pattern. Similarly, AD and psoriasis, although varying in severity over time, are chronic skin diseases, with no permanent cures. When considering topical therapies for long-term prophylaxis, they should be cosmetically acceptable enough to assist in compliance.<sup>29,171</sup> Topical ketoconazole or miconazole may be effective in preventing relapse of SD when used prophylactically once weekly or twice monthly, respectively.<sup>179,180</sup> Oral itraconazole may be effective in the prophylaxis of pityriasis versicolor. Faergemann et al<sup>181</sup> reported that in a 6-month study, itraconazole (400 mg) administered once monthly was effective in the prophylaxis against the recurrence of pityriasis versicolor, in comparison with placebo. Ketoconazole has also been used effectively in prophylactic regimens for pityriasis versicolor, with either single monthly doses of 400 mg or 200 mg once daily for the first 3 days of each month.<sup>182,183</sup>

There is a possibility that the antifungals are helping not just through antiyeast action but by anti-inflammatory mechanisms as well. Thus, research into the immunologic aspects of these diseases may eventually result in a new approach to therapy. In addition, the possibility that only certain *Malassezia* species may be implicated in certain disorders may also have therapeutic relevance. Because the yeasts have different physiologic properties, it may be possible to develop therapies that selectively target the causative species by altering the environment on the hosts' skin. Emollients or lotions that alter the lipid composition on the skin may also affect the amount and kind of *Malassezia* yeasts found on the skin.

## CONCLUSIONS

Our knowledge about the pathogenesis of *Malassezia*-related diseases has increased tremendously during the last decade. Although 7 of the 8 lipophilic *Malassezia* species can be isolated, with varying frequency, from human skin, it appears that the pathologic response is species-specific. The ninth species, *M pachydermatis*, does not need a source of lipid to sustain growth, is able to grow on routine laboratory media, and is rarely implicated in disease of human beings who are immunocom-

petent. Both endogenous and exogenous host factors clearly play a role in the disorders caused by *Malassezia* (pityriasis versicolor, *Malassezia* folliculitis, and SD/D). In AD and psoriasis, evidence suggests that the *Malassezia* yeasts cause an allergic or an inflammatory response on the part of the human host. Several studies have explained the pathogenic mechanism of SD/D, AD, and folliculitis related to *Malassezia* species. This article has reviewed the literature on the involvement of *Malassezia* yeasts in cutaneous disorders and discussed the possibility that different species of these yeasts have different clinical profiles. However, there are several aspects of the immune system, genetics, and skin that remain to be understood with reference to *Malassezia* species. With the help of new molecular approaches, important data are being generated to help understand the pathogenesis of *Malassezia*-related diseases. More species-specific research is required to clarify the role of individual members of the genus *Malassezia* in particular skin disorders.

## REFERENCES

1. Borelli D. [Pityriasis versicolor due to *Malassezia ovalis*]. *Mycopathologia* 1985;89:147-53. Spanish.
2. Faergemann J, Fredriksson T. Experimental infections in rabbits and humans with *Pityrosporum orbiculare* and *P ovale*. *J Invest Dermatol* 1981;77:314-8.
3. Guého E, Midgley G, Guillot J. The genus *Malassezia* with description of four new species. *Antonie Van Leeuwenhoek* 1996;69:337-55.
4. Sugita T, Takashima M, Shinoda T, Suto H, Unno T, Tsuboi R, et al. New yeast species, *Malassezia dermatis*, isolated from patients with atopic dermatitis. *J Clin Microbiol* 2002;40:1363-7.
5. Nell A, James SA, Bond CJ, Hunt B, Herrtage ME. Identification and distribution of a novel *Malassezia* species yeast on normal equine skin. *Vet Rec* 2002;150:395-8.
6. Gupta AK, Kohli Y, Summerbell RC, Faergemann J. Quantitative culture of *Malassezia* species from different body sites of individuals with or without dermatoses. *Med Mycol* 2001;39:243-51.
7. Nakabayashi A, Sei Y, Guillot J. Identification of *Malassezia* species isolated from patients with seborrheic dermatitis, atopic dermatitis, pityriasis versicolor and normal subjects. *Med Mycol* 2000;38:337-41.
8. Gupta AK, Kohli Y, Faergemann J, Summerbell RC. Epidemiology of *Malassezia* yeasts associated with pityriasis versicolor in Ontario, Canada. *Med Mycol* 2001;39:199-206.
9. Gemmer CM, DeAngelis YM, Theelen B, Boekhout T, Dawson JT Jr. Fast, noninvasive method for molecular detection and differentiation of *Malassezia* yeast species on human skin and application of the method to dandruff microbiology. *J Clin Microbiol* 2002;40:3350-7.
10. Gupta AK, Kohli Y, Summerbell RC. Molecular differentiation of seven *Malassezia* species. *J Clin Microbiol* 2000;38:1869-75.
11. Theelen B, Silvestri M, Guého E, Van Belkum A, Boekhout T. Identification and typing of *Malassezia* yeasts using amplified fragment length polymorphism (AFLP), random amplified

- polymorphic DNA (RAPD) and denaturing gradient gel electrophoresis (DGGE). *FEMS Yeast Res* 2001;1:79-86.
12. Boekhout T, Kamp M, Gueho E. Molecular typing of *Malassezia* species with PFGE and RAPD. *Med Mycol* 1998;36:365-72.
  13. Chang HJ, Miller HL, Watkins N, Arduino MJ, Ashford DA, Midgley G, et al. An epidemic of *Malassezia pachydermatis* in an intensive care nursery associated with colonization of health care workers' pet dogs. *N Engl J Med* 1998;338:706-11.
  14. Mickelsen PA, Viano-Paulson MC, Stevens DA, Diaz PS. Clinical and microbiological features of infection with *Malassezia pachydermatis* in high-risk infants. *J Infect Dis* 1988; 157:1163-8.
  15. Van Belkum A, Boekhout T, Bosboom R. Monitoring spread of *Malassezia* infections in a neonatal intensive care unit by PCR-mediated genetic typing. *J Clin Microbiol* 1994;32:2528-32.
  16. Brooks R, Brown L. Systemic infection with *Malassezia furfur* in an adult receiving long-term hyperalimentation therapy. *J Infect Dis* 1987;156:410-1.
  17. Surmont I, Gavilanes A, Vandepitte J, Devlieger H, Eggemont E. *Malassezia furfur* fungaemia in infants receiving intravenous lipid emulsions. A rarity or just underestimated? *Eur J Pediatr* 1989;148:435-8.
  18. Weiss SJ, Schoch PE, Cunha BA. *Malassezia furfur* fungemia associated with central venous catheter lipid emulsion infusion. *Heart Lung* 1991;20:87-90.
  19. Ashbee HR, Evans EG. Immunology of diseases associated with *Malassezia* species. *Clin Microbiol Rev* 2002;15:21-57.
  20. Warner RR, Schwartz JR, Boissy Y, Dawson TL Jr. Dandruff has an altered stratum corneum ultrastructure that is improved with zinc pyrithione shampoo. *J Am Acad Dermatol* 2001;45: 897-903.
  21. Farthing CF, Staughton RCD, Rowland Payne CME. Skin disease in homosexual patients with Acquired Immune Deficiency Syndrome (AIDS) and lesser forms of human T cell Leukaemia Virus (HTLV III) disease. *Clin Exp Dermatol* 1985;10:3-12.
  22. Smith KJ, Skelton HG, Yeager J, Ledsky R, McCarthy W, Baxter D, et al. Cutaneous findings in HIV-1 positive patients: a 42-month prospective study. *J Am Acad Dermatol* 1994;31: 746-54.
  23. Bulmer AC, Bulmer GS. The antifungal action of dandruff shampoos. *Mycopathologia* 1999;147:63-5.
  24. Kligman AM. Perspectives and problems in cutaneous gerontology. *J Invest Dermatol* 1979;73:39-46.
  25. McGrath J, Murphy GM. The control of seborrheic dermatitis and dandruff by antipityrosporal drugs. *Drugs* 1991;41:178-84.
  26. Pierard-Franchimont C, Hermanns JF, Degreef H, Pierard GE. From axioms to new insights into dandruff. *Dermatology* 2000;200:93-8.
  27. Danby FW, Maddin WS, Margesson LJ, Rosenthal D. A randomized, double-blind, placebo-controlled trial of ketoconazole 2% shampoo versus selenium sulfide 2.5% shampoo in the treatment of moderate to severe dandruff. *J Am Acad Dermatol* 1993;29:1008-12.
  28. Priestley GC, Savin JA. The microbiology of dandruff. *Br J Dermatol* 1976;94:469-71.
  29. Faergemann J. Seborrheic dermatitis (dandruff). New York: Marcel Dekker Inc; 2000. p. 197-202.
  30. Shuster S. The aetiology of dandruff and the mode of action of therapeutic agents. *Br J Dermatol* 1984;111:235-42.
  31. Piérard GE, Arrese JE, Piérard-Franchimont C, De Doncker P. Prolonged effects of antidandruff shampoos—time to recurrence of *Malassezia ovalis* colonization of skin. *Int J Cosm Sci* 1997;19:111-7.
  32. Wilson CL, Walshe M. Incidence of seborrheic dermatitis in spinal injury patients. *Br J Dermatol* 1988;119:548.
  33. Cotterill JA, Cunliffe WJ, Williamson B, Bulusu L. Age and sex variation in skin surface lipid composition and sebum excretion rate. *Br J Dermatol* 1972;87:333-40.
  34. Ramasastry P, Downing DT, Pochi PE, Strauss JS. Chemical composition of human skin surface lipids from birth to puberty. *J Invest Dermatol* 1970;54:139-44.
  35. Maysner P, Pape B. Decreased susceptibility of *Malassezia furfur* to UV light by synthesis of tryptophane derivatives. *Antonie Van Leeuwenhoek* 1998;73:315-9.
  36. Maysner P, Schafer U, Kramer HJ, Iringer B, Steglich W. Pityriacitrin—an ultraviolet-absorbing indole alkaloid from the yeast *Malassezia furfur*. *Arch Dermatol Res* 2002;294: 131-4.
  37. Burton JL, Pye RJ. Seborrhea is not a feature of seborrheic dermatitis. *Br Med J* 1983;286:1169-70.
  38. MacKee GM, Lewis GM. Dandruff and seborrhea: I. Flora of "normal" and diseased scalps. *J Invest Dermatol* 1938;1:131-9.
  39. Sabouraud R. *Maladies du cuir chevelu. II. Les maladies desquamatives.* Paris: Masson et cie; 1904.
  40. McGinley KJ, Leyden JJ, Marples RR, Kligman AM. Quantitative microbiology of the scalp in non-dandruff, dandruff, and seborrheic dermatitis. *J Invest Dermatol* 1975;64:401-5.
  41. Bergbrant IM, Faergemann J. Seborrheic dermatitis and *Pityrosporum ovale*: a cultural and immunological study. *Acta Derm Venereol* 1989;69:332-5.
  42. Parry ME, Sharpe GR. Seborrheic dermatitis is not caused by an altered immune response to *Malassezia* yeast. *Br J Dermatol* 1998;139:254-63.
  43. Midgley G, Hay RJ. Serological responses to *Pityrosporum (Malassezia)* in seborrheic dermatitis demonstrated by ELISA and Western blotting. *Bull Soc Fr Mycol Med* 1988; 17:267-76.
  44. Midgley G. The lipophilic yeasts: state of the art and prospects. *Med Mycol* 2000;38:9-16.
  45. Troller JA. Model system for the investigation of dandruff. *J Soc Cosm Chem* 1971;22:187-98.
  46. Binder RL, Jonelis FJ. Seborrheic dermatitis in neuroleptic-induced parkinsonism. *Arch Dermatol* 1983;119:473-5.
  47. Faergemann J, Fredriksson T. Tinea versicolor with regard to seborrheic dermatitis: an epidemiological investigation. *Arch Dermatol* 1979;115:966-8.
  48. Riciputo RM, Oliveri S, Micali G, Sapuppo A. Phospholipase activity in *Malassezia furfur* pathogenic strains. *Mycoses* 1996;39:233-5.
  49. Gueho E, Faergemann J, Lyman C, Anaissie EJ. *Malassezia* and *Trichosporon*: two emerging pathogenic basidiomycetous yeast-like fungi. *J Med Vet Mycol* 1994;32:367-78.
  50. Faergemann J. Management of seborrheic dermatitis and pityriasis versicolor. *Am J Clin Dermatol* 2000;1:75-80.
  51. Hay RJ, Graham-Brown RA. Dandruff and seborrheic dermatitis: causes and management. *Clin Exp Dermatol* 1997;22: 3-6.
  52. Watanabe S, Kano R, Sato H, Nakamura Y, Hasegawa A. The effects of *Malassezia* yeasts on cytokine production by human keratinocytes. *J Invest Dermatol* 2001;116:769-73.
  53. Crespo Erchiga V, Ojeda Martos A, Vera Casano A, Crespo Erchiga A, Sanchez Fajardo F, Guého E. Mycology of pityriasis versicolor. *J Mycol Med* 1999;9:143-8.
  54. Sandström MH, Bartosik J, Bäck O, Scheynius A, Särnhult T, Tengvall Linder M, et al. The prevalence of the *Malassezia*

- yeasts in patients with atopic dermatitis, seborrheic dermatitis and healthy controls. *J Eur Acad Dermatol Venereol* 2001;15:104-274.
55. Kim SC, Kim HU. The distribution of *Malassezia* species on the normal human skin according to body region. *Korean J Med Mycol* 2000;5:120-8.
  56. Gaitanis G, Velegriaki A, Frangoulis E, Mitroussia A, Tsigonia A, Tzimogianni A, et al. Identification of *Malassezia* species from patient skin scales by PCR-RFLP. *Clin Microbiol Infect* 2002;8:162-73.
  57. Sugita T, Suto H, Unno T, Tsuboi R, Ogawa H, Shinoda T, et al. Molecular analysis of *Malassezia* microflora on the skin of atopic dermatitis patients and healthy subjects. *J Clin Microbiol* 2001;39:3486-90.
  58. Michalowski R, Rodziewicz H. Pityriasis versicolor in children. *Br J Dermatol* 1963;75:397-400.
  59. Terragni L, Lasagni A, Oriani A, Gelmetti C. Pityriasis versicolor in the pediatric age. *Pediatr Dermatol* 1991;8:9-12.
  60. Congly H. Pityriasis versicolor in a 3-month-old boy. *Can Med Assoc J* 1984;130:844-5.
  61. Wyre HW Jr, Johnson WT. Neonatal pityriasis versicolor. *Arch Dermatol* 1981;117:752-3.
  62. Stein DH. Superficial fungal infections. *Pediatr Clin North Am* 1983;30:545-61.
  63. Borelli D, Jacobs PH, Nall L. Tinea versicolor: epidemiologic, clinical, and therapeutic aspects. *J Am Acad Dermatol* 1991;25:300-5.
  64. Burke RC. Tinea versicolor: susceptibility factors and experimental infection in human beings. *J Invest Dermatol* 1961;36:389-402.
  65. Faergemann J, Bernander S. Tinea versicolor and *Pityrosporum orbiculare*: a mycological investigation. *Sabouraudia* 1979;17:171-9.
  66. Aste N, Pau M, Aste N, Biggio P. Case report. Pityriasis versicolor mimicking pityriasis rotunda. *Mycoses* 2002;45:126-8.
  67. Desruelles F, Gari-Toussaint M, Lacour JP, Marty P, Le Fichoux Y, Ortonne JP. Tinea versicolor mimicking pityriasis rotunda. *Int J Dermatol* 1999;38:948-9.
  68. Ena P, Siddi GM. Pityriasis versicolor resembling pityriasis rotunda. *J Eur Acad Dermatol Venereol* 2002;16:85-7.
  69. Glazer SD, Zuger C. Tinea versicolor of the face. *Cutis* 1980;26:87.
  70. El Gotham Z, Ghazzi M. Tinea versicolor of the scalp. *Int J Dermatol* 1995;34:533-4.
  71. Goncalves AP. Unusual locations of pityriasis versicolor with particular reference to scalp lesion. *Dermatol Trop* 1963;2:211-6.
  72. Anthony JL, Schosser RH, Gross DJ. Unilateral areolar and periareolar tinea versicolor. *Int J Dermatol* 1991;30:600.
  73. Blumenthal HL. Tinea versicolor of the penis. *Arch Dermatol* 1971;103:461-2.
  74. Payle B, Serrano L, Bielek HC, Reyes BA. Albert's solution versus potassium hydroxide solution in the diagnosis of tinea versicolor. *Int J Dermatol* 1994;33:182-3.
  75. McGinley KJ, Lantis LR, Marples RR. Microbiology of tinea versicolor. *Arch Dermatol* 1970;102:168-71.
  76. Savin R. Diagnosis and treatment of tinea versicolor. *J Fam Pract* 1996;43:127-32.
  77. Mayser P, Pickel M, Haze P, Erdmann F, Papavassilis C, Schmidt R. Different utilization of neutral lipids by *Malassezia furfur* and *Malassezia sympodialis*. *Med Mycol* 1998;36:7-14.
  78. Weiss R, Raabe P, Mayser P. Yeasts of the genus *Malassezia*: taxonomic classification and significance in (veterinary and) clinical medicine. [in German]. *Mycoses* 2000;43:69-72.
  79. Crespo EV, Ojeda MA, Vera CA, Crespo EA, Sanchez FF. *Malassezia globosa* as the causative agent of pityriasis versicolor. *Br J Dermatol* 2000;143:799-803.
  80. Back O, Faergemann J, Hornqvist R. *Pityrosporum* folliculitis: a common disease of the young and middle-aged. *J Am Acad Dermatol* 1985;12:56-61.
  81. Katoh T, Irimajiri J. Pityriasis versicolor and *Malassezia* folliculitis. *Nippon Ishinkin Gakkai Zasshi* 1999;40:69-71.
  82. Leeming JP, Holland KT, Cunliffe WJ. The microbial ecology of pilosebaceous units isolated from human skin. *J Gen Microbiol* 1984;130:803-7.
  83. Jacinto-Jamora S, Tamesis J, Katigbak ML. *Pityrosporum* folliculitis in the Philippines: diagnosis, prevalence, and management. *J Am Acad Dermatol* 1991;24:693-6.
  84. Back O, Scheynius A, Johansson SG. Ketoconazole in atopic dermatitis: therapeutic response is correlated with decrease in serum IgE. *Arch Dermatol Res* 1995;287:448-51.
  85. Gueho E, Boekhout T, Ashbee HR, Guillot J, Van Belkum A, Faergemann J. The role of *Malassezia* species in the ecology of human skin and as pathogens. *Med Mycol* 1998;36:220-9.
  86. Faergemann J, Johansson S, Back O, Scheynius A. An immunologic and cultural study of *Pityrosporum* folliculitis. *J Am Acad Dermatol* 1986;14:429-33.
  87. Lim KB, Giam YC, Tan T. The epidemiology of *Malassezia (Pityrosporum)* folliculitis in Singapore. *Int J Dermatol* 1987;26:438-41.
  88. Sina B, Kauffman CL, Samorodin CS. Intrafollicular mucin deposits in *Pityrosporum* folliculitis. *J Am Acad Dermatol* 1995;32:807-9.
  89. Faergemann J, Bergbrant IM, Dohse M, Scott A, Westgate G. Seborrheic dermatitis and *Pityrosporum (Malassezia)* folliculitis: characterization of inflammatory cells and mediators in the skin by immunohistochemistry. *Br J Dermatol* 2001;144:549-56.
  90. Potter BS, Burgoon CF Jr, Johnson WC. *Pityrosporum* folliculitis: report of seven cases and review of the *Pityrosporum* organism relative to cutaneous disease. *Arch Dermatol* 1973;107:388-91.
  91. Hill MK, Goodfield JD, Rodgers FG, Crowley JL, Saihan EM. Skin surface electron microscopy in *Pityrosporum* folliculitis: the role of follicular occlusion in disease and the response to oral ketoconazole. *Arch Dermatol* 1990;126:181-4.
  92. Bufill JA, Lum LG, Caya JG, Chitambar CR, Ritch PS, Anderson T, et al. *Pityrosporum* folliculitis after bone marrow transplantation: clinical observations in five patients. *Ann Intern Med* 1988;108:560-3.
  93. Rhie S, Turcios R, Buckley H, Suh B. Clinical features and treatment of *Malassezia* folliculitis with fluconazole in orthotopic heart transplant recipients. *J Heart Lung Transplant* 2000;19:215-9.
  94. Yohn JJ, Lucas J, Camisa C. *Malassezia* folliculitis in immunocompromised patients. *Cutis* 1985;35:536-8.
  95. Fearfield LA, Rowe A, Francis N, Bunker CB, Staughton RC. Itchy folliculitis and human immunodeficiency virus infection: clinicopathological and immunological features, pathogenesis and treatment. *Br J Dermatol* 1999;141:3-11.
  96. Ferrandiz C, Ribera M, Barranco JC, Clotet B, Lorenzo JC. Eosinophilic pustular folliculitis in patients with acquired immunodeficiency syndrome. *Int J Dermatol* 1992;31:193-5.
  97. Faergemann J. Atopic dermatitis and fungi. *Clin Microbiol Rev* 2002;15:545-63.
  98. Williams HC, Burney PGJ, Pembroke AC, Hay RJ. The UK Working Party's diagnostic criteria for atopic dermatitis. III. Independent hospital validation. *Br J Dermatol* 1994;131:406-16.

99. Williams HC. Epidemiology of atopic dermatitis. *Clin Exp Dermatol* 2000;5:522-9.
100. Thestrup-Pedersen K. The incidence and pathophysiology of atopic dermatitis. *J Eur Acad Dermatol Venereol* 1996;7:53-7.
101. Broberg A, Faergemann J, Johansson S, Johansson SG, Strannegard IL, Svejgaard E. *Pityrosporum ovale* and atopic dermatitis in children and young adults. *Acta Derm Venereol* 1992;72:187-92.
102. Clemmensen OJ, Hjorth N. Treatment of atopic dermatitis of the head and neck with ketoconazole in patients with type I sensitivity to *P orbiculare*. *Semin Dermatol* 1983;2:26-9.
103. Doekes G, van Ieperen-van Dijk AG. Allergens of *Pityrosporum ovale* and *Candida albicans*. I. Cross-reactivity of IgE-binding components. *Allergy* 1993;48:394-400.
104. Devos SA, van der Valk PG. The relevance of skin prick tests for *Pityrosporum ovale* in patients with head and neck dermatitis. *Allergy* 2000;55:1056-8.
105. Faergemann J. *Pityrosporum* species as a cause of allergy and infection. *Allergy* 1999;54:413-9.
106. Huang X, Johansson SG, Zargari A, Nordvall SL. Allergen cross-reactivity between *Pityrosporum orbiculare* and *Candida albicans*. *Allergy* 1995;50:648-56.
107. Jensen-Jarolim E, Poulsen LK, With H, Kieffer M, Ottevanger V, Stahl SP. Atopic dermatitis of the face, scalp, and neck: type I reaction to the yeast *Pityrosporum ovale*? *J Allergy Clin Immunol* 1992;89:44-51.
108. Johansson C, Sandstrom MH, Bartosik J, Sarnhult T, Christiansen J, Zargari A, et al. Atopy patch test reactions to *Malassezia* allergens differentiate subgroups of atopic dermatitis patients. *Br J Dermatol* 2003;148:479-88.
109. Kroger S, Neuber K, Gruseck E, Ring J, Abeck D. *Pityrosporum ovale* extracts increase interleukin-4, interleukin-10 and IgE synthesis in patients with atopic eczema. *Acta Derm Venereol* 1995;75:357-60.
110. Rokugo M, Tagami H, Usuba Y, Tomita Y. Contact sensitivity to *Pityrosporum ovale* in patients with atopic dermatitis. *Arch Dermatol* 1990;126:627-32.
111. Savolainen J, Lintu P, Kosonen J, Kortekangas-Savolainen O, Viander M, Pene J, et al. *Pityrosporum* and *Candida* specific and non-specific humoral, cellular and cytokine responses in atopic dermatitis patients. *Clin Exp Allergy* 2001;31:125-34.
112. Scalabrin DM, Bavbek S, Perzanowski MS, Wilson BB, Platts-Mills TA, Wheatley LM. Use of specific IgE in assessing the relevance of fungal and dust mite allergens to atopic dermatitis: a comparison with asthmatic and nonasthmatic control subjects. *J Allergy Clin Immunol* 1999;104:1273-9.
113. Waersted A, Hjorth N. *Pityrosporum orbiculare*—a pathogenic factor in atopic dermatitis of the face, scalp and neck? *Acta Derm Venereol Suppl (Stockh)* 1985;114:146-8.
114. Back O, Bartosik J. Systemic ketoconazole for yeast allergic patients with atopic dermatitis. *J Eur Acad Dermatol Venereol* 2001;15:34-8.
115. Kieffer M, Bergbrant IM, Faergemann J, Jemec GB, Ottevanger V, Stahl SP, et al. Immune reactions to *Pityrosporum ovale* in adult patients with atopic and seborrheic dermatitis. *J Am Acad Dermatol* 1990;22:739-42.
116. Tengvall LM, Johansson C, Scheynius A, Wahlgren C. Positive atopy patch test reactions to *Pityrosporum orbiculare* in atopic dermatitis patients. *Clin Exp Allergy* 2000;30:122-31.
117. Schmidt M, Zargari A, Holt P, Lindbom L, Hellman U, Whitley P, et al. The complete cDNA sequence and expression of the first major allergenic protein of *Malassezia furfur*, Mal f 1. *Eur J Biochem* 1997;246:181-5.
118. Yasueda H, Hashida-Okado T, Saito A, Uchida K, Kuroda M, Onishi Y, et al. Identification and cloning of two novel allergens from the lipophilic yeast, *Malassezia furfur*. *Biochem Biophys Res Commun* 1998;248:240-4.
119. Kim TY, Jang IG, Park YM, Kim HO, Kim CW. Head and neck dermatitis: the role of *Malassezia furfur*, topical steroid use and environmental factors in its causation. *Clin Exp Dermatol* 1999;24:226-31.
120. Lindgren L, Wahlgren CF, Johansson SG, Wiklund I, Nordvall SL. Occurrence and clinical features of sensitization to *Pityrosporum orbiculare* and other allergens in children with atopic dermatitis. *Acta Derm Venereol* 1995;75:300-4.
121. McGregor JM, Hamilton AJ, Hay RJ. Possible mechanisms of immune modulation in chronic dermatophytoses: an in vitro study. *Br J Dermatol* 1992;127:233-8.
122. Rasool O, Zargari A, Almqvist J, Eshaghi H, Whitley P, Scheynius A. Cloning, characterization and expression of complete coding sequences of three IgE binding *Malassezia furfur* allergens, Mal f 7, Mal f 8 and Mal f 9. *Eur J Biochem* 2000;267:4355-61.
123. Zargari A, Midgley G, Back O, Johansson SG, Scheynius A. IgE-reactivity to seven *Malassezia* species. *Allergy* 2003;58:306-11.
124. Koyama T, Kanbe T, Ishiguro A, Kikuchi A, Tomita Y. Antigenic components of *Malassezia* species for immunoglobulin E antibodies in sera of patients with atopic dermatitis. *J Dermatol Sci* 2001;26:201-8.
125. Doekes G, Kaal MJ, van Ieperen-van Dijk AG. Allergens of *Pityrosporum ovale* and *Candida albicans*. II. Physicochemical characterization. *Allergy* 1993;48:401-8.
126. Johansson S, Karlstrom K. IgE-binding components in *Pityrosporum orbiculare* identified by an immunoblotting technique. *Acta Derm Venereol* 1991;71:11-6.
127. Savolainen J, Lammintausta K, Kalimo K, Viander M. *Candida albicans* and atopic dermatitis. *Clin Exp Allergy* 1993;23:332-9.
128. Lintu P, Savolainen J, Kalimo K. IgE antibodies to protein and mannan antigens of *Pityrosporum ovale* in atopic dermatitis patients. *Clin Exp Allergy* 1997;27:87-95.
129. Wessels MW, Doekes G, Van Ieperen-Van Kijk AG, Koers WJ, Young E. IgE antibodies to *Pityrosporum ovale* in atopic dermatitis. *Br J Dermatol* 1991;125:227-32.
130. Zargari A, Harfast B, Johansson S, Johansson SG, Scheynius A. Identification of allergen components of the opportunistic yeast *Pityrosporum orbiculare* by monoclonal antibodies. *Allergy* 1994;49:50-6.
131. Kanbe T, Koyama T. Atopic dermatitis and *Malassezia* species: a study of antigenic components *Malassezia* species for immunoglobulin E of patients with atopic dermatitis. *Nippon Ishinkin Gakkai Zasshi* 2003;44:61-4.
132. Cox H, Cookson WOCM, Harper J. Genetic of atopic dermatitis. In: Harper J, Oranje A, Prose N, editors. *Pediatric dermatology*. Oxford: Blackwell Science; 2000. p. 169-77.
133. Koyama T, Kanbe T, Ishiguro A, Kikuchi A, Tomita Y. Isolation and characterization of a major antigenic component of *Malassezia globosa* to IgE antibodies in sera of patients with atopic dermatitis. *Microbiol Immunol* 2000;44:373-9.
134. Abeck D, Mempel M. *Staphylococcus aureus* colonization in atopic dermatitis and its therapeutic implications. *Br J Dermatol* 1998;139:13-6.
135. Brook I, Frazier EH, Yeager JK. Microbiology of infected atopic dermatitis. *Int J Dermatol* 1996;35:791-3.
136. Goh CL, Wong JS, Giam YC. Skin colonization of *Staphylococcus aureus* in atopic dermatitis patients seen at the National Skin Centre, Singapore. *Int J Dermatol* 1997;36:653-7.

137. Klein PA, Clark RAF, Nicol NH. Acute infection with *Trichophyton rubrum* associated with flares of atopic dermatitis. *Cutis* 1999;63:171-2.
138. Skov L, Baadsgaard O. The potential role of *Staphylococcus aureus* superantigens in atopic eczema. *J Eur Acad Dermatol Venereol* 1996;7:58-11.
139. Lubbe J. Secondary infections in patients with atopic dermatitis. *Am J Clin Dermatol* 2003;4:641-54.
140. Van de Kerkhof PC, Franssen ME. Psoriasis of the scalp: diagnosis and management. *Am J Clin Dermatol* 2001;2:159-65.
141. Rosenberg EW, Belew PW. Improvement of psoriasis of the scalp with ketoconazole. *Arch Dermatol* 1982;118:370-1.
142. Rosenberg EW, Noah PW, Skinner RB Jr, Vander ZR, West SK, Browder JF. Microbial associations of 167 patients with psoriasis. *Acta Derm Venereol Suppl (Stockh)* 1989;146:72-4.
143. Mayser P, Schutz M, Schuppe HC, Jung A, Schill WB. Frequency and spectrum of *Malassezia* yeasts in the area of the prepuce and glans penis. *BJU Int* 2001;88:554-8.
144. Ackerman AB. Histopathologic differentiation of eczematous dermatitides from psoriasis and seborrheic dermatitis. *Cutis* 1977;20:619-23.
145. Baker BS, Powles A, Garioch JJ, Hardman C, Fry L. Differential T-cell reactivity to the round and oval forms of *Pityrosporum* in the skin of patients with psoriasis. *Br J Dermatol* 1997;136:319-25.
146. Squiquera L, Galimberti R, Morelli L, Plotkin L, Milicich R, Kowalczuk A, et al. Antibodies to proteins from *Pityrosporum ovale* in the sera from patients with psoriasis. *Clin Exp Dermatol* 1994;19:289-93.
147. Kanda N, Tani K, Enomoto U, Nakai K, Watanabe S. The skin fungus-induced Th1- and Th2-related cytokine, chemokine and prostaglandin E2 production in peripheral blood mononuclear cells from patients with atopic dermatitis and psoriasis vulgaris. *Clin Exp Allergy* 2002;32:1243-50.
148. Prohic A. Identification of *Malassezia* species isolated from scalp skin of patients with psoriasis and healthy subjects. *Acta Dermatovenerol Croat* 2003;11:10-6.
149. Gougerot H, Carteaude A. Papillomatose pigmentée innommée. *Bull Soc Fr Dermatol Syph* 1927;34:719-21.
150. Nordby CA, Mitchell AJ. Confluent and reticulated papillomatosis responsive to selenium sulfide. *Int J Dermatol* 1986;25:194-9.
151. Yesudian P, Kamalam S, Razack A. Confluent and reticulated papillomatosis (Gougerot-Carteaud): an abnormal host reaction to *Malassezia furfur*. *Acta Derm Venereol* 1973;53:381-4.
152. Segal R, Alteras I, Sandbank M. Rapid response of transient acantholytic dermatosis to selenium sulfide treatment for pityriasis versicolor. *Dermatologica* 1987;175:205-7.
153. Crozier WJ, Wise KA. Onychomycosis due to *Pityrosporum*. *Australas J Dermatol* 1993;34:109-12.
154. Silva V, Moreno GA, Zaror L, de Oliveira E, Fischman O. Isolation of *Malassezia furfur* from patients with onychomycosis. *J Med Vet Mycol* 1997;35:73-4.
155. Kinnunen T, Koskela M. Antibacterial and antifungal properties of propylene glycol, hexylene glycol, and 1,3-butylene glycol in vitro. *Acta Derm Venereol* 1991;71:148-50.
156. McGinley KJ, Leyden JJ. Antifungal activity of dermatological shampoos. *Arch Dermatol Res* 1982;272:339-42.
157. Van Cutsem J, van Gerven F, Franssen J, Schrooten P, Janssen PA. The in vitro antifungal activity of ketoconazole, zinc pyrithione, and selenium sulfide against *Pityrosporum* and their efficacy as a shampoo in the treatment of experimental pityrosporiasis in guinea pigs. *J Am Acad Dermatol* 1990;22:993-8.
158. Warren R, Schwartz JR, Sanders LM, Juneja PS. Attenuation of surfactant-induced interleukin-1alpha expression by zinc pyrithione. *Exog Dermatol* 2003;2:23-7.
159. Gupta AK, Batra R, Bluhm R, Faergemann J. Pityriasis versicolor. *Dermatol Clin* 2003;21:413-29.
160. Gupta AK, Bluhm R, Cooper EA, Summerbell RC, Batra R. Seborrheic dermatitis. *Dermatol Clin* 2003;21:401-12.
161. Uchida K, Nishiyama Y, Tanaka T, Yamaguchi H. In vitro activity of novel imidazole antifungal agent NND-502 against *Malassezia* species. *Int J Antimicrob Agents* 2003;21:234-8.
162. Vardy DA, Zvulunov A, Tchetov T, Biton A, Rosenman D. A double-blind, placebo-controlled trial of a ciclopirox olamine 1% shampoo for the treatment of scalp seborrheic dermatitis. *J Dermatol Treat* 2000;11:73-7.
163. Faergemann J, Hersle K, Nordin P. Pityriasis versicolor: clinical experience with Lamisil cream and Lamisil DermGel. *Dermatology* 1997;194:19-21.
164. Gupta AK. Butenafine: an update of its use in superficial mycoses. *Skin Therapy Lett* 2002;7:1-5.
165. Ling MR. Topical tacrolimus and pimecrolimus: future directions. *Semin Cutan Med Surg* 2001;20:268-74.
166. Nakagawa H, Etoh T, Yokota Y, Ikeda F, Hatano K, Teratani N, et al. Tacrolimus has antifungal activities against *Malassezia furfur* isolated from healthy adults and patients with atopic dermatitis. *Clin Drug Invest* 1996;12:245-50.
167. Savin RC. Systemic ketoconazole in tinea versicolor: a double-blind evaluation and 1-year follow-up. *J Am Acad Dermatol* 1984;10:824-30.
168. Urcuyo FG, Zaias N. The successful treatment of pityriasis versicolor by systemic ketoconazole. *J Am Acad Dermatol* 1982;6:24-5.
169. Ford GP, Farr PM, Ive FA, Shuster S. The response of seborrheic dermatitis to ketoconazole. *Br J Dermatol* 1984;111:603-7.
170. Ford GP, Ive FA, Midgley G. *Pityrosporum* folliculitis and ketoconazole. *Br J Dermatol* 1982;107:691-5.
171. Caputo R, Barbareschi M. Itraconazole: new horizons. *G Ital Dermatol Venereol* 2002;137:1-7.
172. Robertson LI. Itraconazole in the treatment of widespread tinea versicolor. *Clin Exp Dermatol* 1987;12:178-80.
173. Rigopoulos D, Katsambas A, Antoniou C, Polydorou D, Vlachou M, Stratigos J. Tinea versicolor treated with fluconazole shampoo. *Int J Dermatol* 1992;31:664-5.
174. Rigopoulos D, Katsambas A, Antoniou C, Theocharis S, Stratigos J. Facial seborrheic dermatitis treated with fluconazole 2% shampoo. *Int J Dermatol* 1994;33:136-7.
175. Scaparro E, Quadri G, Virno G, Orifici C, Milani M. Evaluation of the efficacy and tolerability of oral terbinafine (Daskil) in patients with seborrheic dermatitis. A multicentre, randomized, investigator-blinded, placebo-controlled trial. *Br J Dermatol* 2001;144:854-7.
176. Faergemann J, Zehender H, Denouel J, Millerioux L. Levels of terbinafine in plasma, stratum corneum, dermis-epidermis (without stratum corneum), sebum, hair and nails during and after 250 mg terbinafine orally once per day for four weeks. *Acta Derm Venereol* 1993;73:305-9.
177. Gupta AK, Kohli Y, Li A, Faergemann J, Summerbell RC. In vitro susceptibility of the seven *Malassezia* species to ketoconazole, voriconazole, itraconazole and terbinafine. *Br J Dermatol* 2000;142:758-65.
178. Johnson BA, Nunley JR. Treatment of seborrheic dermatitis. *Am Fam Physician* 2000;61:2703-4.

179. Faergemann J. Seborrhoeic dermatitis and *Pityrosporum orbiculare*: treatment of seborrhoeic dermatitis of the scalp with miconazole-hydrocortisone (Daktacort), miconazole and hydrocortisone. Br J Dermatol 1986;114:695-700.
180. Peter RU, Richarz-Barthauer U. Successful treatment and prophylaxis of scalp seborrhoeic dermatitis and dandruff with 2% ketoconazole shampoo: results of a multicentre, double-blind, placebo-controlled trial. Br J Dermatol 1995; 132:441-5.
181. Faergemann J, Gupta AK, Al Mofadi A, Abanami A, Shareeah AA, Marynissen G. Efficacy of itraconazole in the prophylactic treatment of pityriasis (tinea) versicolor. Arch Dermatol 2002; 138:69-73.
182. Faergemann J, Djarv L. Tinea versicolor: treatment and prophylaxis with ketoconazole. Cutis 1982;30:542-50.
183. Rausch LJ, Jacobs PH. Tinea versicolor: treatment and prophylaxis with monthly administration of ketoconazole. Cutis 1984;34:470-1.