

Systemic mycosis caused by a new *Cladophialophora* species

K. TINTELNOT,* P. VON HUNNIUS,† G. S. DE HOOG,‡ A. POLAK-WYSS,§ E. GUÉHO¶ & F. MASCLAUX¶

*Robert Koch-Institut, Nordufer 20, 13353 Berlin, Germany; †Klinik Loewenstein, 74245 Loewenstein, Kreis Heilbronn, Germany; ‡Centraalbureau voor Schimmelcultures, PO Box 273, 3740 AG Baarn, the Netherlands; §Hoffmann-La Roche, Grenzacherstr. 124, 4002 Basel, Switzerland; and ¶Unité de Mycologie, Institut Pasteur, 28 rue du Dr Roux, 75726 Paris Cedex 15, France

A 22-year-old woman suffered from haemoptyses of unknown aetiology. A tumour in the lingula was diagnosed histologically to be a granulomatosis, most likely a sarcoidosis. Two years later, the patient returned with dyspnoea caused by a granulomatous tumour in the trachea, histologically similar to that seen earlier. After bronchoscopic laser resection, cortisone therapy was applied but without success. A fungus was subsequently discovered histologically and was cultivated from biopsy specimens. Retrospective research of primary histological slides led to the conclusion that a mycosis was the initial cause of the tumours. The mycosis was successfully treated with high-dose itraconazole for 1 year, combined with 5-fluorocytosine (5-FC) during the first few months. The causative agent was found to be a new species of *Cladophialophora*, and is described as *C. arxii* Tintelnot; its key characteristics are presented.

Introduction

Pulmonary granulomata may have divergent aetiologies. In the absence of acid-fast bacilli, which would prove to be tuberculosis, a differential diagnosis should consider sarcoidosis. An aetiology of mycotic origin should also be taken into consideration is demonstrated by the following case history. The difficulties in revealing the true nature of the disorder presented below suggest that such mycoses might actually be more common than is currently supposed.

The aetiological agent proved to be a melanized hyphomycete with conidia in chains and could be classified in the genus *Cladophialophora* Borelli. Our isolate was included in the panel of strains studied, in view of the taxonomic revision of the genus, published elsewhere in this issue [1]. It could not be identified with any of the accepted taxa, and is therefore described below as a new species.

Materials and methods

Physiology

We employed the methods of nutritional physiology as described by de Hoog *et al.* [2]. Briefly, growth and fermentative abilities were tested in duplicate in a liquid medium, rocked in a nearly horizontal position or kept stationary, respectively. Assimilation test results were read at weekly intervals by comparison with positive and negative controls. Urease was tested on Christensen's agar. Halotolerance and growth with cycloheximide was tested in a liquid medium; the latter test was also carried out on commercial Mycosel agar (Becton Dickinson, Cockeysville, MD).

Molecular methods

Sequences of 577 nucleotides of LS rRNA were obtained by indirect sequencing with the aid of reverse transcriptase, as described by Masclaux *et al.* [1]. Sequences were aligned with all types or authentic strains of *Cladophialophora* species. The guanine plus cytosine (GC) content of DNA in 0.1XSSC was determined by thermo-denaturation using a Gilford Response II

Correspondence: K. Tintelnot, Robert Koch-Institut, Nordufer 20, 13353 Berlin, Germany. Tel.: +49 30 45472208; Fax: +49 30 45472614.

spectrophotometer [1]. DNA/DNA reassociation experiments were carried out with the same equipment using an optical technique.

Susceptibility testing

The agar dilution method was employed, with yeast morphology agar (YMA) as the medium [3,4]. Minimum inhibitory concentrations (MICs) were determined from serial dilutions involving 1:3 (single drugs) or 1:2 (combined drugs) dilution steps. 5-Fluorocytosine (5-FC) and amphotericin B were dissolved in water, itraconazole was dissolved in dimethylsulphoxide and all drugs were gradually diluted in distilled water. Drug dilutions were mixed with liquid agar which was allowed to harden in slanted tubes. The inoculum concentration consisted of 10^3 – 10^4 viable particles per ml of final medium. MICs were read after 48 h, 72 h and 6 days incubation at 30 °C.

Case report

A 22-year-old Philippine woman, who has been living in Germany for 3 years, suffered from haemoptyses of unknown origin. An X-ray revealed a tumour, 5 cm in diameter, in her left lung. An excision of the lingula was performed. The removed granulomatous tissue disclosed clusters of epithelial cells, giant cells of Langhans type, and fibrosis. Minute central necroses were observed, although without a cheese-like texture. Fungal elements were not seen, and cultures for mycobacteria remained negative. There was no indication of immunodeficiency. Therefore, the diagnosis was thought to be sarcoidosis, which was treated with corticosteroids for a short period.

One year later one of the supraclavicular lymph nodes appeared swollen and was surgically removed. Histologically, the earlier diagnosis of sarcoidosis was confirmed. A year later, the patient, now in her sixth month of pregnancy, was hospitalized because of acute dyspnoea. A critical stenosing tumour was seen in the distal trachea and was partly removed by laser- and electro-coagulation. The histology of the biopsy specimens was similar to that of the excised lingula tissue from 2 years earlier. A renewed, high-dose cortisone therapy was initiated, but growth was still subsequently observed. In further biopsy specimens, fungal cells were seen for the first time. The cells were pigmented and broadly ellipsoidal to subcylindrical; they occasionally joined together in short chains and hyphal elements were also present (Fig. 1). The culturing of biopsy specimens (Fig. 2) on Sabouraud's glucose agar (SGA) after 4 days yielded a single colony at 26 °C and several colonies at 37 °C. These colonies were dry, mouse grey, and consisted of hydrophobic chains of lemon-shaped conidia; conidiophores were

undifferentiated (Fig. 3). The fungus was tentatively identified as a *Cladosporium* species.

Because of the patient's pregnancy, antimycotic therapy was—under regular clinical surveillance—postponed until after delivery. Two days after the onset of chemotherapy with daily 600 mg itraconazole and 150 mg 5-FC, an abdominal abscess was observed between the spleen and the left colonflexure. Fungi were detected by microscopy and culture. The abscess was surgically removed in the fourth week of antimycotic therapy. Within 6 weeks, bronchoscopic observation revealed a cessation of growth, termination of bleeding, and subsequently a regression of the tracheal tumour. After a 6 week period of antimycotic therapy, biopsy specimens taken from the affected area at regular intervals revealed no more dark brown, but hyaline, small, ovoidal fungal cells, while culturing remained positive. Antimycotic therapy was continued with 2×200 mg itraconazole daily *per os* for 12 months. A final control after 1 year's treatment showed an intact mucosa of the trachea without granulomata. A biopsy demonstrated only a slight fibrosing bronchitis and a small group of giant cells. The patient still has no clinical symptoms 2 years after the termination of chemotherapy.

In vitro susceptibility testing

Strain CBS 306-94 was inhibited by 5-FC, amphotericin B and itraconazole, although in varying degrees: MICs for 5-FC and amphotericin B were $30 \mu\text{g ml}^{-1}$, for itraconazole $10 \mu\text{g ml}^{-1}$. A synergistic effect was demonstrated with 5-FC and itraconazole. This combination showed a fractional inhibitory concentration index (FIC) of 0.3, which indicates an additive or even synergistic effect (FIC values < 0.5 are synergistic according to Elion *et al.* [5]).

Discussion

The clinical course of this case demonstrates some difficulties in the diagnosis of rare mycoses. From the outset the possibility of a mycosis was taken into consideration, but cultures from bronchial lavage and sputum remained negative. In the resected tissue from the lingula, fungi were not immediately recognized. Retrospective analysis of several tissue and biopsy specimens, however, showed that dark, muriform cells of the aetiological agent had been present (Fig. 4).

The portal of entry of the fungi could not be established with certainty. The pulmonary process could possibly indicate an infection through inhalation. However, the patient had a subcutaneous tumour at her knee during childhood in the Philippines, similar to the

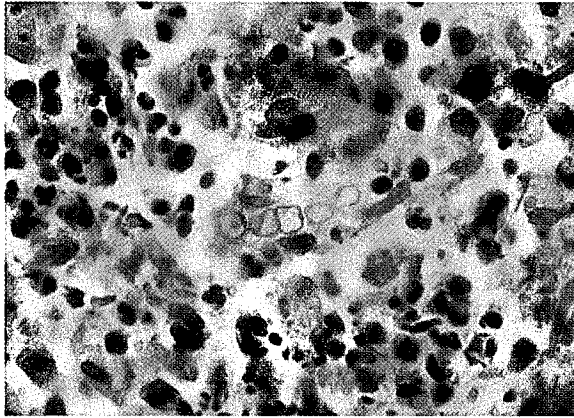


Fig. 1 Initial biopsy specimen showing a short chain of melanized inflated cells (H&E × 1250).

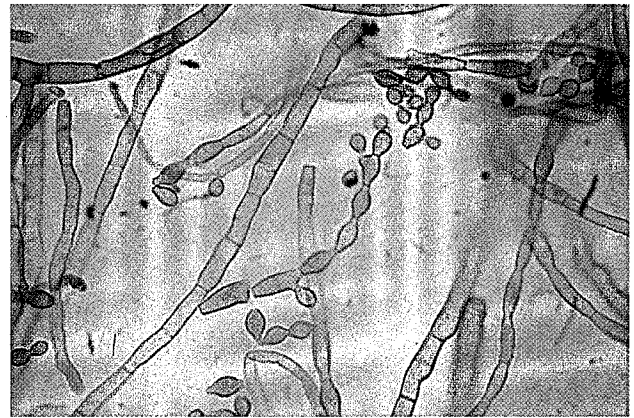

Fig. 2 Hyphae present in necrotic tissue after corticosteroid therapy (unstained × 1250).




Fig. 3 Morphology of a conidial chain of the fungal culture on beerwort-agar, 21 days at 32 °C (× 1250).

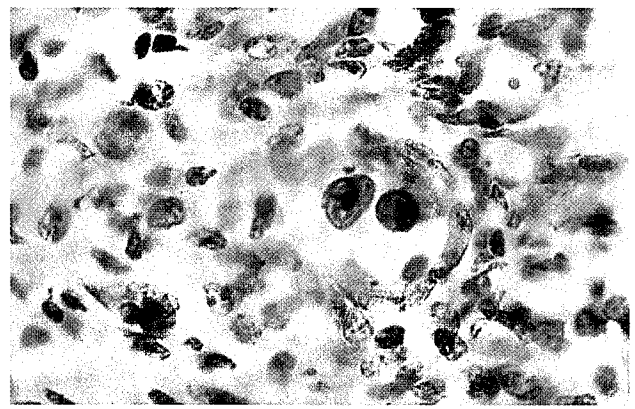


Fig. 4 Biopsy specimen of the resected tumour of the lingo showing muriform, dark brown fungal cells (H&E × 1250).

supraclavicular tumour many years later. This might indicate a dissemination of a traumatically inoculated fungus. At admission only a scar was present at the knee.

Because infections with black yeast-like fungi are known to be extremely chronic [6,7], therapy was extended for several months. The clinical history of our case also demonstrates the importance of long-term antimycotic treatment. Because of pregnancy, chemotherapy could not be started after the mycosis was diagnosed. During this period, growth of the granulomata and haemoptyses were noted. Within 6 weeks of treatment with itraconazole and 5-FC, the haemoptyses ceased. After the abdominal abscess (which developed before chemotherapy) was removed by surgical intervention, no further dissemination was observed. The combination of 5-FC and itraconazole has proved to be of beneficial value in chromoblastomycoses caused by *Fonsecaea pedrosoi* [8,9 and A. Restrepo, personal communication]. Both the clinical outcome and the *in vitro* data of our case suggest

that an additive or even synergistic effect of 5-FC and itraconazole can also be observed in cases of *Cladophialophora* mycoses. The patient tolerated the chemotherapy for 1 year; no side-effects were noted.

The identification of the *Cladosporium*-like fungus was problematic. Species distinction in pathogenic *Cladosporium* species (recently reclassified in a separate genus, *Cladophialophora* Borelli [2]) rests on clinical pathology [10], histopathological characteristics [10], morphology [11] and physiology [2].

Cladophialophora carrionii (Trejos) de Hoog *et al.* [2] is an agent of cutaneous chromoblastomycosis, histologically characterized by muriform cells in the tissue. *Cladophialophora bantiana* (Sacc.) de Hoog *et al.* [2] is a neurotropic species [12], while *Cladophialophora devriesii* (Padhye) de Hoog *et al.* [2] is identified by a single, disseminated case without involvement of the central nervous tissue [13,14]. *C. devriesii* and *C. bantiana* form regular hyphae in tissue [14]. The name *Xylohypha*

emmonsii Padhye *et al.* was used until recently for agents of subcutaneous phaeohyphomycosis characterized by irregularly swollen conidia, but it is now known as a synonym of *C. bantiana* [1,2]. Consequently, the histopathological appearance of this species is dependent on the invaded tissue, hyphae being regular in deep organs but irregularly swollen in (sub)cutaneous tissue. Thus, histopathological features are probably linked to differences in local immunity. The fungus in our case is remarkable because it initially showed muriform cells in the tissue (Fig. 4), similar to those known in *C. carrionii*, but under corticosteroid therapy the fungal growth changed to irregular hyphal elements (Fig. 1), as found in subcutaneous infections by *C. bantiana*. This might indicate that the histopathological appearance of *Cladophialophora* species might be partly dependent on the patient's immunological status.

Morphologically, our strain differs from *Cladophialophora bantiana* by having fragile conidial chains borne on denticles, and physiologically, by not assimilating methyl- α -glucoside, soluble starch, glycerol, meso-erythritol, myo-inositol and succinate [2]. *C. devriesii* has slightly smaller, Saturn-shaped conidia arranged in relatively short chains, which are often borne on denticles [1,2]. This species is morphologically closely related to our strain, although it is slightly smaller on average. This species is also nearly identical in its nutritional physiology, most differences being quantitative [2]. A notable difference is that *C. devriesii* is unable to grow at temperatures above 37 °C. This is confirmed by differences in partial 26S rRNA sequences and a low nDNA/DNA reassociation [1]. The *Cladophialophora* synanamorph of *Exophiala dermatitidis* (Kano) de Hoog [15], reported from a mycosis of the liver [16] differs by being unable to assimilate nitrate and nitrite [17].

On the basis of the above differences, we conclude that our strain represents a hitherto undescribed species. It is classified in the genus *Cladophialophora*, as circumscribed by de Hoog *et al.* [2] for human-pathogenic species of herpotrichiellaceous relationship.

Cladophialophora arxii Tintelnot, sp. nov.—Figs 3 and 5

Coloniae in agar PCA dicto post 5 dies 30 °C 9 mm diam., coactae vel velutinae, griseo-olivaceae, margine translucido regulari 1 mm lato praeditae; reversum in medio olivaceo-nigrum. Hyphae repentes primum subhyalinae, cito olivascentes, omnino regulariter 2–3 μ m latae, intervallis 20–30 μ m septatae. Hyphae adscendentes olivaceo-brunneae, leves et fere crassitunicatae; ramos conidiales laterales ferentes; in parte distali in ramoconidia et series conidorum transeuntes. Apparatus

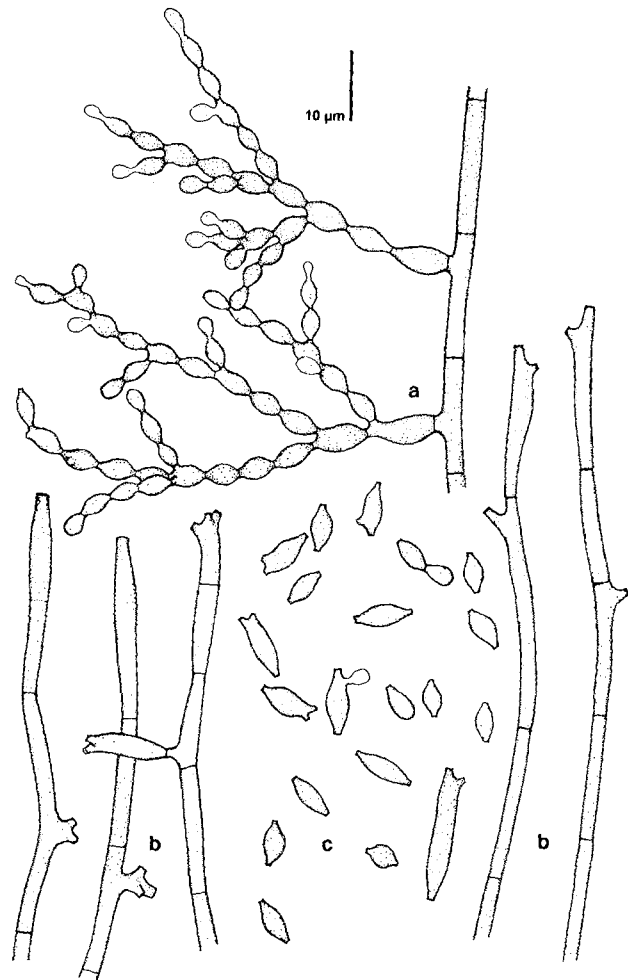


Fig. 5 Morphology after slide cultures on PCA, 5 days at 30 °C. (a) Conidial apparatus; (b) ascending hyphae showing conidium-bearing denticles; (c) random selection of liberated conidia.

conidialis ex catenis profuse ramosis acropetaliter elongascentibus constans; rami seu sessiles seu e denticulis singulis vel furcatis, 5 μ m longis, oriundi; cicatrices circa 1 μ m diam., pigmentatione aequales atque paries hypharum propinquarum. Conidia brunnea, levia, fere crassitunicata, limoniformia vel fusiformia, utrinque distincte angustata, in parte distali 1–3 cicatrices ferentia, plerumque 7–15 \times 3–4 μ m. Chlamydo sporae pallide brunneae et corpora multicellularia circa 15 μ m diam. in acido producta. Habitus physiologici in Tab. 1 collati.

Typus (siccus et vivus) CBS 306-94, isolatus a P. von Hunnius e trachea humana, Loewenstein in Germania.

Colonies (PCA, 30 °C) attaining 9 mm diam in 5 days, dry, evenly felty to velvety, greyish-olivaceous, with flat, transparent margin 1 mm wide; reverse centrally olivaceous-black. Creeping hyphae initially subhyaline, soon becoming olivaceous-brown, evenly 2–3 μ m wide

Table 1 Physiological properties of *Cladophialophora arxii***Fermentation: absent****Assimilation**

D-glucose	+	Lactose	+	D-gluconate	+
D-galactose	+	Raffinose	+	D-glucuronate	+
L-sorbose	+	Melezitose	+	D-galacturonate	+
D-glucosamine	–	Inulin	–	DL-lactate	–
D-ribose	+	Soluble starch	w	Succinate	w
D-xylose	+	Glycerol	+	Citrate	+
L-arabinose	+	meso-erythritol	+	Methanol	–
D-arabinose	+	Ribitol	w	Ethanol	–
L-rhamnose	+	Xylitol	+	Nitrate	+
Sucrose	+	L-arabinitol	w	Nitrite	+
Maltose	+	D-glucitol	+	Ethylamine	+
α,α -trehalose	+	D-mannitol	+	L-lysine	+
methyl- α -glucoside	w	Galactitol	+	Cadaverine	+
Cellobiose	+	myo-inositol	+	Creatine	+
Salicin	+	Gluc- β -lactone	+	Creatinine	+
Arbutin	+	2-keto-D-gluconate	w	Ammonia	–
Melibiose	+	5-keto-D-gluconate	+		

Remaining tests

10% MgCl ₂	w	Urease	+
10% NaCl	–	Starch production	–
0.1% Cycloheximide	+	40 °C growth	+
Mycosel	+		

+, positive; –, negative; w, weak.

throughout, regularly septate every 20–30 μm . Ascending hypae olivaceous-brown, smooth- and rather firm-walled, with lateral conidial branches, in the distal part changing over into ramo-conidia and terminating by a series of conidia. Conidial system composed of profusely branched, acropetally elongating conidial chains; branches sessile or borne on acuminate or forked denticles up to 5 μm in length; scars about 1 μm wide, with the same pigmentation as the adjacent cell walls. Conidia brown, smooth- and rather firm-walled, limoniform to fusiform, distinctly tapered towards both ends, distally with 1–4 scars, mostly 7–15 \times 3–4 μm depending on the localization in the chain. Pale brown chlamydo spores and multicellular bodies about 15 μm diam. produced at low pH.

Physiological properties of the species are listed in Table 1. Type strain (living and dried): CBS 306-94, ex biopsy specimen from human trachea lesion, Loewenstein, Germany, P. von Hunnius.

Etymology

Named after the late Dr J. A. von Arx, former CBS director, acknowledging his contributions towards resolving the taxonomy of *Cladosporium*.

Acknowledgements

The authors extend their gratitude to Dr H. G. Laberke and Dr P. Holch for making histological preparations available for study.

References

- Masclaux F, Guého E, de Hoog GS, Christen R. Phylogenetic relationships of human-pathogenic *Cladosporium* (*Xylohypha*) species inferred from partial LS rRNA sequences. *J Med Vet Mycol* 1995; **33**: 327–38.
- de Hoog GS, Guého E, Masclaux F, Gerrits van den Ende AHG, Kwon-Chung KJ, McGinnis MR. Nutritional physiology and taxonomy of human-pathogenic *Cladosporium-Xylohypha* species. *J Med Vet Mycol* 1995; **33**: 339–47.
- Dixon DM, Polak A. *In vitro* and *in vivo* drug studies with three agents of central nervous system phaeohyphomycosis. *Chemotherapy* 1987; **33**: 129–40.
- Polak A. Antimycotic therapy of experimental infections caused by dematiaceous fungi. *Sabouraudia* 1984; **22**: 279–89.
- Elion GB, Singer S, Hitchings GH. Antagonists of nucleic acid derivatives. VIII. Synergism in combinations of biochemically-related antimetabolites. *J Biol Chem* 1954; **208**: 477–88.
- Kumar B, Kaur I, Chakrabarti A, Sharma VK. Treatment of deep mycoses with itraconazole. *Mycopathologia* 1991; **115**: 169–74.
- Restrepo A, Gonzalez A, Gomez I, Arango M, de Bedout C. Treatment of chromoblastomycosis with itraconazole. *Ann NY Acad Sci* 1988; **544**: 504–16.

- 8 Borelli D. A clinical trial of itraconazole in the treatment of deep mycoses and leishmaniasis. *Rev Infect Dis* 1987; **9** (Suppl. 1): S57-63.
- 9 Moulin G, Cognat Th, Ferrier E, Alligier H. Chromomycose: efficacité de l'association itraconazole + 5-fluorocytosine. *J Dermatol Paris* 1989; **14**: 54-7.
- 10 Kwon-Chung KJ, de Vries GA. Comparative study of an isolate resembling Banti's fungus with *Cladosporium trichoides*. *Sabouraudia* 1983; **21**: 59-72.
- 11 de Hoog GS, Guarro J. *Atlas of Clinical Fungi*. Baarn, Netherlands: Centraalbureau voor Schimmelcultures, 1995.
- 12 Heney C, Song E, Kellen A, Raal F, Miller SD, Davis V. Cerebral phaeohyphomycosis caused by *Xylohypha bantiana*. *Eur J Clin Microbiol Infect Dis* 1989; **8**: 984-8.
- 13 Gonzalez MS, Alfonso B, Seckinger D, Padhye AA, Ajello L. Subcutaneous phaeohyphomycosis caused by *Cladosporium devriesii*, sp. nov. *Sabouraudia* 1984; **22**: 427-32.
- 14 Mitchell DM, Fitz-Henley M, Horner-Bryce J. A case of disseminated phaeohyphomycosis caused by *Cladosporium devriesii*. *West Indian Med J* 1990; **39**: 118-23.
- 15 de Hoog GS, Takeo K, Göttlich E, Nishimura K, Miyaji M. A human isolate of *Exophiala (Wangiella) dermatitidis* forming a catenate synanamorph that links the genera *Exophiala* and *Cladophialophora*. *J Med Vet Mycol* 1995; **33**: 355-8.
- 16 Takahashi Y, Takahashi S, Fukushi G, Kobayashi K. A case, in which a pathogenic dematiaceous fungus forming a yeast-like colony was isolated from the liver. *Japan J Med Mycol* 1966; **7**: 42-8.
- 17 de Hoog GS, Haase G. Nutritional physiology and selective isolation of *Exophiala dermatitidis*. *Antonie van Leeuwenhoek* 1993; **64**: 17-26.